

Spontaneous puberty in 46,XX subjects with congenital lipoid adrenal hyperplasia. Ovarian steroidogenesis is spared to some extent despite inactivating mutations in the steroidogenic acute regulatory protein (StAR) gene.

K Fujieda, ... , T Sugawara, J F Strauss 3rd

J Clin Invest. 1997;99(6):1265-1271. <https://doi.org/10.1172/JCI119284>.

Research Article

Congenital lipoid adrenal hyperplasia (lipoid CAH) is the most severe form of CAH in which the synthesis of all gonadal and adrenal cortical steroids is markedly impaired. We report here the clinical, endocrinological, and molecular analyses of two unrelated Japanese kindreds of 46,XX subjects affected with lipoid CAH who manifested spontaneous puberty. Phenotypic female infants with 46,XX karyotypes were diagnosed with lipoid CAH as newborns based on a clinical history of failure to thrive, hyperpigmentation, hyponatremia, hyperkalemia, and low basal values of serum cortisol and urinary 17-hydroxycorticosteroid and 17-ketosteroid. These patients responded to treatment with glucocorticoid and 9alpha-fludrocortisone. Spontaneous thelarche occurred in association with increased serum estradiol levels at the age of 10 and 11 yr, respectively. Pubic hair developed at the age of 12 yr 11 mo in one subject and menarche was at the age of 12 yr in both cases. Both subjects reported periodic menstrual bleeding and subsequently developed polycystic ovaries. To investigate the molecular basis of the steroidogenic lesion in these patients, the StAR gene was characterized by PCR and direct DNA sequence analyses. DNA sequence analysis revealed that one patient is homozygous for the Gln 258 Stop mutation in exon 7 and that the other patient is a compound heterozygote with the Gln 258 Stop mutation and a single A deletion at codon 238 in [...]

Find the latest version:

<https://jci.me/119284/pdf>



Spontaneous Puberty in 46,XX Subjects with Congenital Lipoid Adrenal Hyperplasia

Ovarian Steroidogenesis Is Spared to Some Extent Despite Inactivating Mutations in the Steroidogenic Acute Regulatory Protein (StAR) Gene

Kenji Fujieda,* Toshihiro Tajima,* Jun Nakae,* Shunichi Sageshima,† Katsuhiko Tachibana,§ Seizou Suwa,§ Teruo Sugawara,|| and Jerome F. Strauss III||

*Department of Pediatrics, Hokkaido University School of Medicine, Sapporo, Japan 060; †Department of Pediatrics, Obihiro Kousei Hospital, Obihiro, Japan 080; ‡Division of Endocrinology and Metabolism, Kanagawa Children's Medical Center, Yokohama, Japan 232; and §Department of Obstetrics and Gynecology, University of Pennsylvania Medical Center, Philadelphia, Pennsylvania 19104

Abstract

Congenital lipoid adrenal hyperplasia (lipoid CAH) is the most severe form of CAH in which the synthesis of all gonadal and adrenal cortical steroids is markedly impaired. We report here the clinical, endocrinological, and molecular analyses of two unrelated Japanese kindreds of 46,XX subjects affected with lipoid CAH who manifested spontaneous puberty. Phenotypic female infants with 46,XX karyotypes were diagnosed with lipoid CAH as newborns based on a clinical history of failure to thrive, hyperpigmentation, hyponatremia, hyperkalemia, and low basal values of serum cortisol and urinary 17-hydroxycorticosteroid and 17-ketosteroid. These patients responded to treatment with glucocorticoid and 9 α -fludrocortisone. Spontaneous thelarche occurred in association with increased serum estradiol levels at the age of 10 and 11 yr, respectively. Pubic hair developed at the age of 12 yr 11 mo in one subject and menarche was at the age of 12 yr in both cases. Both subjects reported periodic menstrual bleeding and subsequently developed polycystic ovaries. To investigate the molecular basis of the steroidogenic lesion in these patients, the StAR gene was characterized by PCR and direct DNA sequence analyses. DNA sequence analysis revealed that one patient is homozygous for the Gln 258 Stop mutation in exon 7 and that the other patient is a compound heterozygote with the Gln 258 Stop mutation and a single A deletion at codon 238 in the other allele causing a frame-shift, which renders the StAR protein nonfunctional. These findings demonstrate that ovarian steroidogenesis can be spared to some extent through puberty when the StAR gene product is inactive. This is in marked contrast to the early onset of severe defects in testicular and adrenocortical steroidogenesis which are characteristics of this disease. (*J. Clin. Invest.* 1997; 99: 1265–1271.) Key words: lipoid adrenal hyperplasia • spontaneous puberty • StAR • steroidogenesis • ovary

Address correspondence to Kenji Fujieda, M.D., Ph.D., Department of Pediatrics, Hokkaido University School of Medicine, N-15,W-7, Kita-ku, Sapporo, Japan 060. Phone: 81-11-716-1161 x5954; FAX: 81-11-736-9267; E-mail: ken-fuji@med.hokudai.ac.jp

Received for publication 7 November 1996 and accepted in revised form 7 January 1997.

J. Clin. Invest.

© The American Society for Clinical Investigation, Inc.

0021-9738/97/03/1265/07 \$2.00

Volume 99, Number 6, March 1997, 1265–1271

Introduction

Congenital lipoid adrenal hyperplasia (lipoid CAH)¹ is the most severe form of CAH. It is characterized by impaired synthesis of all the adrenal steroids including mineralocorticoids, glucocorticoids, and sex steroids (1). Affected individuals are phenotypically female and have severe salt wasting (1–4). Based on endocrine profiles and in vitro studies, the metabolic lesion in this disease was localized to the first step of steroidogenesis (1–4). In mitochondria of adrenal cortex and gonads, the conversion of cholesterol to pregnenolone is catalyzed by the cholesterol side-chain cleavage enzyme (P450_{scc}) supported by its electron transport system consisting of NADPH-adrenodoxin reductase and adrenodoxin (1, 5). Because mitochondria from affected adrenal glands and gonads fail to convert cholesterol to pregnenolone, the disease had been thought to be caused by a defect in P450_{scc} (1–4). However, defects in P450_{scc}, adrenodoxin, and adrenodoxin reductase were eliminated by molecular genetic analysis of affected patients (5–7). Recently, the gene for steroidogenic acute regulatory protein (StAR), which functions as a labile protein factor in steroidogenesis mediating cholesterol transport within mitochondria, was cloned (8–10). Mutations in the StAR gene were subsequently identified as the cause of lipoid CAH (8, 11).

Although 46,XY individuals with lipoid CAH fail to develop male external genitalia and do not go through spontaneous puberty, some genetic females with lipoid CAH have been reported to undergo spontaneous pubertal changes (12). In this report, we describe the clinical, endocrinological, and molecular analyses of two 46,XX females with lipoid CAH, who went through spontaneous puberty and subsequently had cyclical menstrual bleeding. The unique features of these subjects document StAR-independent steroidogenesis in the ovary.

Methods

Case histories

Kindred 1. The only affected member of family 1 was a 21-yr-old genetic female. There was no history of consanguinity, but the first phenotypically female offspring of the parents died in the first month of life of unknown causes. The patient was first referred to Hokkaido University Hospital at the age of 2 mo because of failure to thrive, weakness, and increased skin pigmentation. Physical examination dis-

1. *Abbreviations used in this paper:* FSH, follicle-stimulating hormone; 17-KS, 17-ketosteroid; LH-RH, luteinizing hormone-releasing hormone; lipoid CAH, congenital lipoid adrenal hyperplasia; 17-OHCS, 17-hydroxycorticosteroid; StAR, gene for steroidogenic acute regulatory protein.

closed normal female external genitalia. Initial laboratory studies revealed a serum sodium of 131 meq/liter and potassium of 6.9 meq/liter. Urinary excretions of 17-ketosteroid (17-KS) and 17-hydroxycorticosteroid (17-OHCS) were 1.39 and 2.77 $\mu\text{mol/d}$, respectively (17-KS, normal range 0.42–1.04 $\mu\text{mol/d}$, 17-OHCS, normal range 3.32–6.73 $\mu\text{mol/d}$). Serum cortisol levels showed no response to the intravenous administration of 0.25 mg ACTH. In addition, the plasma ACTH concentration was extremely high (> 264 pmol/liter). On the basis of these findings, the infant was diagnosed as having lipoid CAH and was treated with hydrocortisone, 9 α -fludrocortisone, and NaCl. She has responded well to replacement therapy. At the age of 5 yr, the patient was admitted again for hormonal evaluation. A karyo-

type obtained at this time was 46,XX. Serum adrenocortical steroids and urinary 17-KS and 17-OHCS did not respond to the intramuscular administration of 0.5 mg ACTH-Z for 3 d. At this time, a luteinizing hormone-releasing hormone (LH-RH) stimulation test gave peak values of LH and follicle-stimulating hormone (FSH) of 20.1 and 60 IU/liter, respectively (LH, normal range 2.2–6.5 IU/liter; FSH, normal range 9.2–25.5 IU/liter at this prepubertal stage), demonstrating an exaggerated response. At 10 yr of age, the patient manifested Tanner stage II breast development. At this time, the LH-RH stimulation test gave peak values of LH and FSH of 89.2 and 16.2 IU/liter, respectively (LH, normal range 15.0–30.7 IU/liter; FSH, normal range 6.5–17.2 IU/liter at this pubertal stage). At this time, her serum estradiol

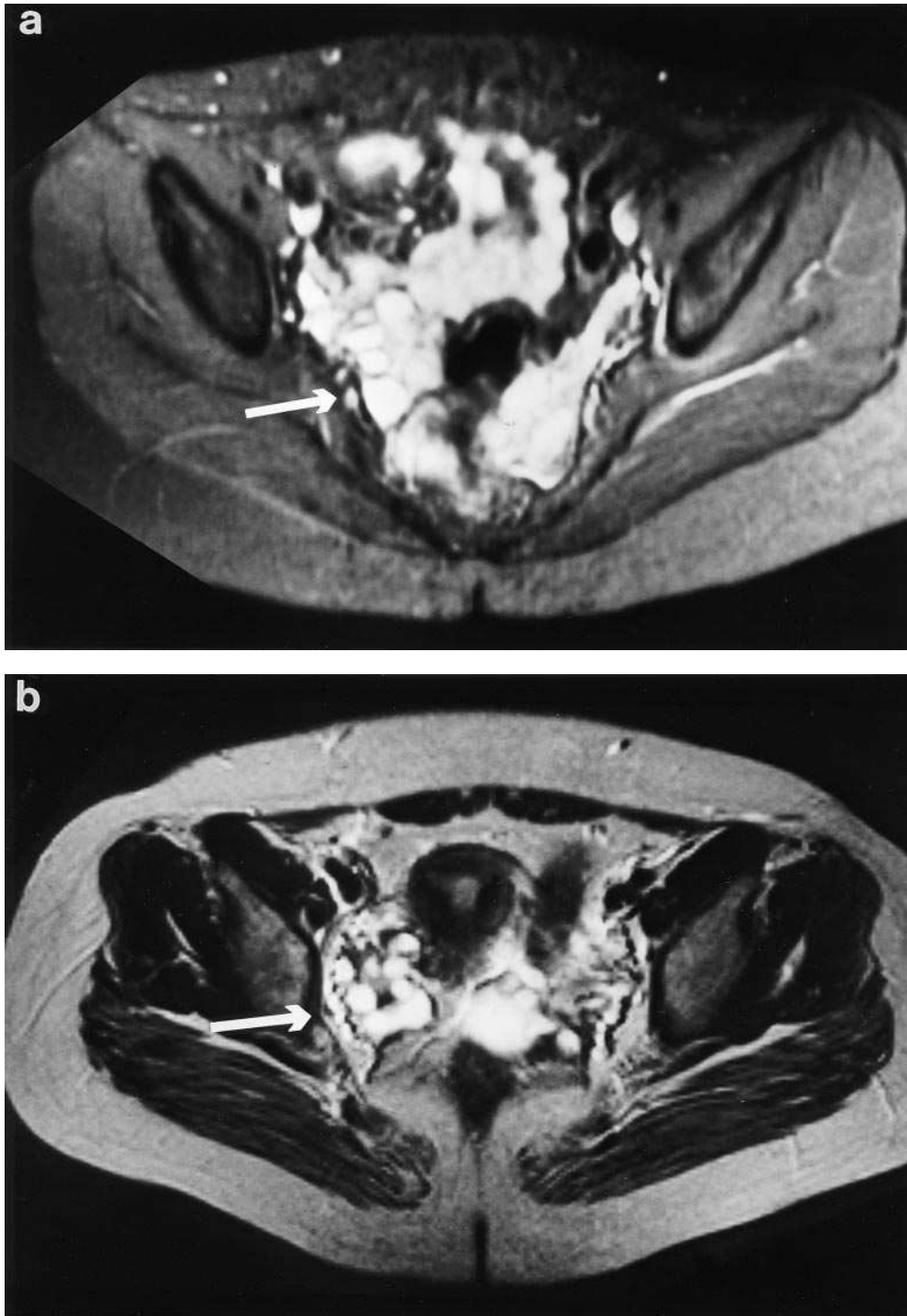


Figure 1. MRI of ovaries in the patients from kindred 1 (a) and kindred 2 (b). MRI was performed on a 1.5-T permanent magnet. The arrows indicate ovaries. In T2w sequence in the axial plane both ovaries are enlarged with many cysts occupying the entire volume of the ovary and hypertrophied ovarian stroma.

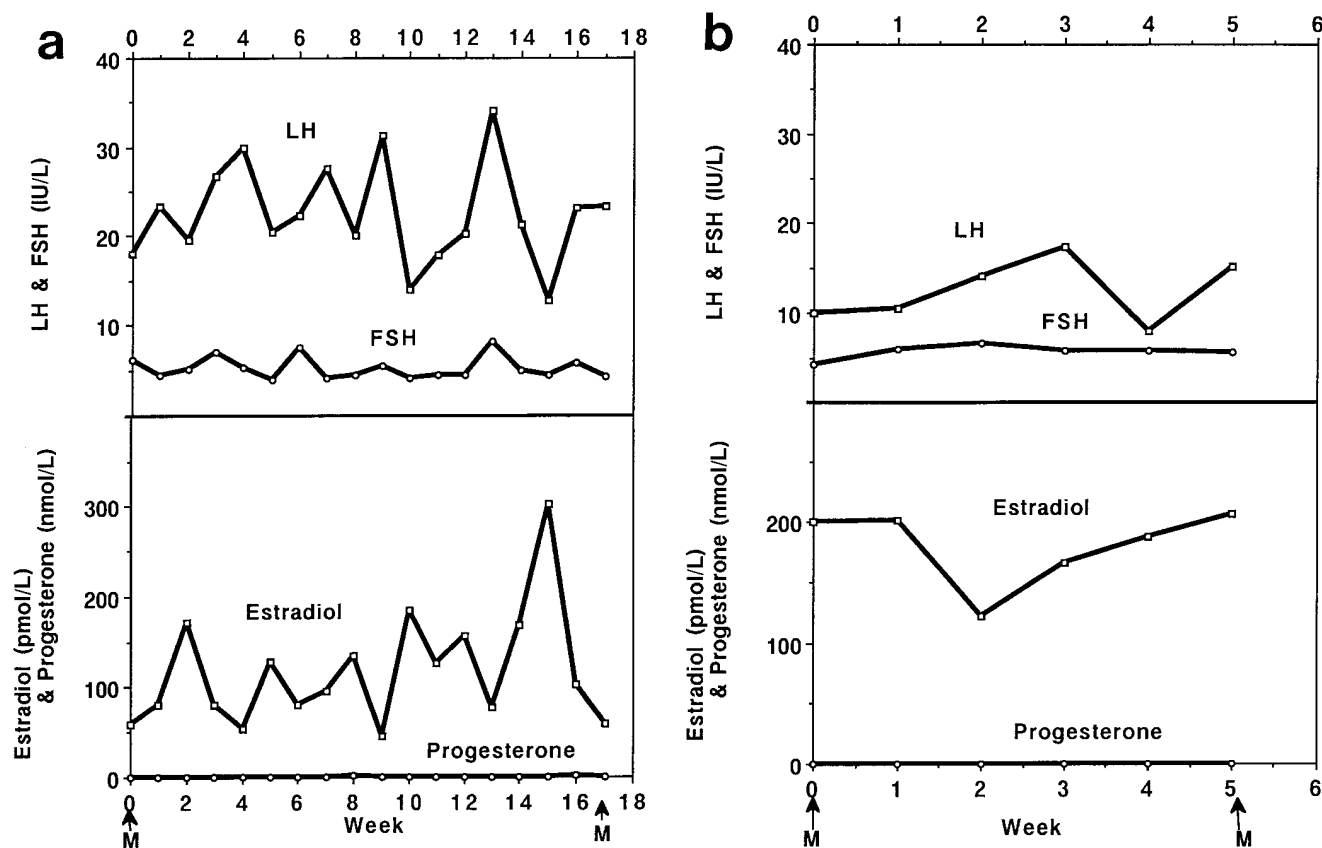


Figure 2. Endocrine profiles of patients from kindred 1 (a) and kindred 2 (b). In both subjects, LH levels were modestly elevated. Estradiol was detectable, but progesterone was not detected. Furthermore, DHEA, DHEAS, androstenedione, 17-OH progesterone, and testosterone were not detected. M indicates menstrual bleeding.

level was < 36.7 pmol/liter. Menarche occurred at the age of 12 yr when a serum estradiol concentration was 139.5 pmol/liter. The LH-RH stimulation test yielded peak values of LH and FSH of 61.3 and 10.8 IU/liter, respectively (LH, normal range 15.0–30.7 IU/liter; FSH, normal range 6.5–17.2 IU/liter at this pubertal stage). Stage II pubic hair appeared at the age of 12 yr 11 mo. At the age of 13 yr, the patient's height was 151 cm, at the 10th percentile for adult Japanese females. At evaluation at 15 yr of age the patient reported periodic vaginal bleeding. Breasts developed to Tanner stage III, but pubic hair remained at stage II. Pelvic ultrasonography identified appropriately sized uterus and ovaries for an adult Japanese female. At the age of 20 yr, abdominal MRI revealed polycystic changes in the ovary (Fig. 1 a). The patient's endocrine profile during a menstrual cycle is shown in Fig. 2 a. LH levels were increased whereas FSH levels were not elevated. Although serum estradiol levels fluctuated from 73 to 294 pmol/liter, progesterone remained undetectable. DHEA (< 0.03 nmol/liter), DHEAS (< 0.02 μ mol/liter), androstenedione (< 0.03 nmol/liter), 17-OH progesterone (< 0.45 nmol/liter), and testosterone (< 0.14 nmol/liter) were also not detectable.

Kindred 2. The propositi of family 2 were two genetic female siblings. There was no history of consanguinity, but the first phenotypically female offspring of the parents died at 2 d of age of unknown causes. The older female subject studied was the product of an uneventful birth at 40 wk of gestation with a birth weight of 2,450 g. Although she was recognized to be slightly pigmented and fed poorly, she was discharged at 7 d of life. 3 wk later, she presented with weight loss, hyponatremia, and hyperkalemia, suggesting hypoadrenalism. She was treated with hydrocortisone and NaCl supplementation. She was then referred to Kanagawa Children's Medical Center for further evaluation at the age of 38 d. At this examination, her skin was ob-

served to be pigmented and she had normal female genitalia with a karyotype of 46,XX. Endocrinological examination revealed elevated plasma ACTH (131 pmol/liter, upper limit of normal: 22 pmol/liter) and plasma renin activity (6.16 ng/(liter·s), upper limit of normal: 1.39 ng/(liter·s) and undetectable cortisol (< 28 nmol/liter), aldosterone (< 69 pmol/liter), 17-hydroxyprogesterone (< 0.45 nmol/liter), and urinary 17-OHCS (< 2.1 μ mol/d) and 17-ketosteroids (< 2.6 μ mol/d), suggesting defective production of all three classes of adrenal steroid hormones. She was diagnosed as having lipoid CAH. Since then, she has been treated with hydrocortisone, 9 α -fludrocortisone, and NaCl. At 11 yr of age, the patient manifested Tanner stage II breast development. Menarche occurred at the age of 12 yr. At this time, values of LH and FSH were 6.9 and 2.9 IU/liter and serum estradiol was 201 pmol/liter. At the age of 14 yr, her height was 145.8 cm, at the 1%tile for adult Japanese females. At evaluation at 16 yr of age, the patient reported cyclic vaginal bleeding. Pelvic ultrasonography identified normal sized ovaries and uterus for an adult Japanese female. The patient's endocrine profile during a menstrual cycle is shown in Fig. 2 b. LH levels were modestly elevated, as was found in the subject in kindred 1. Serum estradiol levels were > 110 pmol/liter, but progesterone remained undetectable (Fig. 2 b). DHEA (< 0.03 nmol/liter), DHEAS (< 0.02 μ mol/liter), androstenedione (< 0.03 nmol/liter), 17-OH progesterone (< 0.45 nmol/liter), and testosterone (< 0.14 nmol/liter) were not detectable. Pubic hair has not appeared by the age of 16 yr and breast development remained at Tanner stage II. At the age of 16 yr, abdominal MRI revealed polycystic changes in the ovaries (Fig. 1 b).

The younger sister of this patient was a 2,540-g product of an uneventful 40-wk gestation. She manifested generalized skin pigmentation with normal female genitalia at birth. This patient was suspected

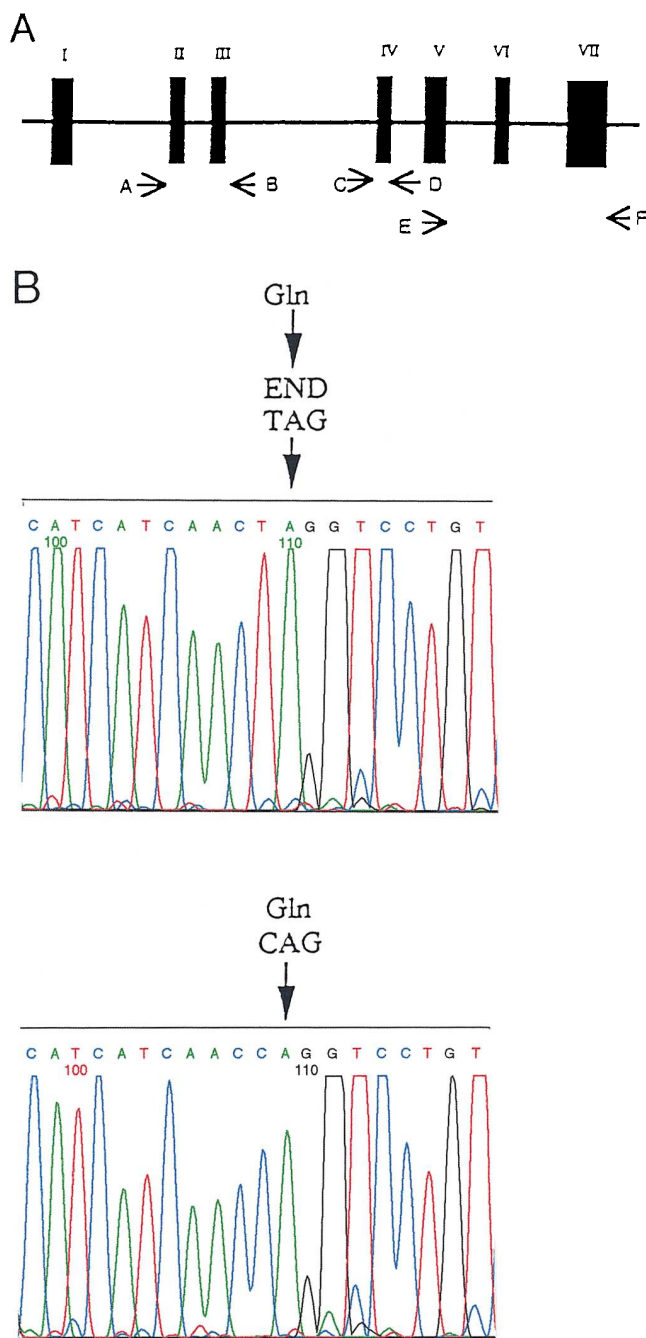


Figure 3. (A) Schematic representation of the human StAR gene structure and amplification strategy. The numbered boxes represent the exons. Black boxes indicate the coding regions. The locations of oligonucleotide primers A–F for amplification are demonstrated by arrows. PCR products from primer pairs A and B, C and D, and E and F were sequenced using an automated DNA sequencer (Applied Biosystems, Inc.) using the *Taq* DyeDeoxy sequencing reagents. (B) Partial nucleotide sequence of exon 7 of the StAR gene in kindred 1. The arrowheads indicate the site of the mutation (Gln 258 Stop). A wild-type sequence is also shown.

to have lipoid CAH because the elder sister had been diagnosed with the disease. By 8 d of life, she had shown poor weight gain, hyponatremia, and hyperkalemia. The karyotype was 46,XX. Further endocrinological evaluation confirmed that the younger sister also

had lipoid CAH. She had Tanner stage II breast development at the age of 9 yr. She has not menstruated at her present age of 13 yr.

Genetic analyses

To analyze the StAR gene, genomic DNA was obtained from white blood cells by standard procedures. The exons and exon-intron boundaries of the StAR gene were amplified by PCR using oligonucleotide primers as follows: primer A: 5'-GTCCCTGCTAGAATACTGTGTT-3'; primer B: 5'-GACTGCTGCATGAGACAGGA-3'; primer C: 5'-TGCTGGGATTAAGGCGTGAAC-3'; primer D: 5'-GCTAGGGTCCCTCTCTTTGATACAG-3'; primer E: 5'-GTGAGCAAA-GTCCAGGTGCG-3'; primer F: 5'-ATGAGCGTGTGTACCAGTGCAG-3'. These primers were designed on the basis of the recent characterization of the human StAR gene (10). The locations of the PCR primers are illustrated in Fig. 3 A. PCR with primer pairs of A and B, and C and D using a Perkin-Elmer/Cetus Thermal Cycler (Perkin-Elmer, Norwalk, CT) was performed as follows: 35 cycles of 1 min at 94 °C, 2 min at 58 °C and 3 min at 72 °C. PCR for primer pairs E and F was carried out for 35 cycles of 94 °C for 1 min, 63 °C for 2 min, and 72 °C for 3 min. PCR products from primer pairs of A and B, C and D, and E and F were resolved by 1.5% agarose gel electrophoresis and directly sequenced using an automated DNA sequencer (Applied Biosystems, Inc., Foster City, CA) using *Taq* DyeDeoxy sequencing reagents (Applied Biosystems, Inc.).

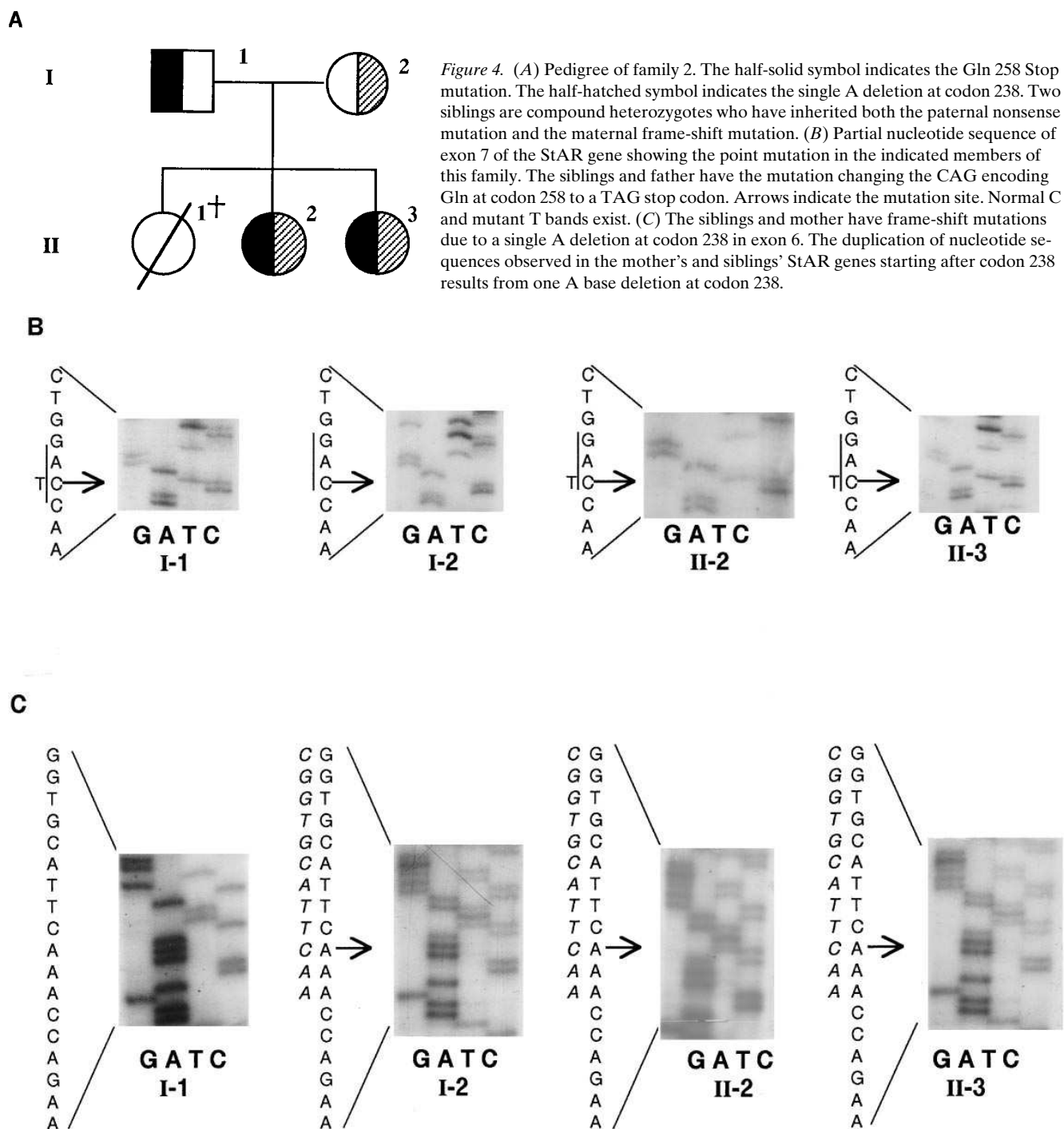
Functional studies

The wild-type human StAR cDNA and the mutant cDNA with a single A base deletion out of three A bases at codon 238 were cloned into the pSV-SPORT-1 vector to yield the plasmids pStAR and p238 del A. Nonsteroidogenic COS-1 cells were cultured to 40% confluence in 35-mm plastic dishes and were transfected with 1 µg of pSV-SPORT-1, pStAR, or p238 del A and 1 µg of plasmid F2, which expresses the fusion protein H2N-P450scc-adrenodoxin reductase-adrenodoxin-COOH, kindly provided by Dr. Walter L. Miller (University of California, San Francisco), using 10 µl of lipofectamine as described previously (8). 48 h after transfection, the culture medium was collected for assays of pregnenolone by RIA. We did not carry out in vitro expression studies of the mutant StAR protein with the Gln 258 Stop mutation in exon 7, because Lin et al. (8) demonstrated previously that the resulting truncated StAR protein is not functional in this in vitro assay. Western blot analyses on mitochondrial fractions isolated from transfected COS-1 cell extracts were carried out as described previously using an antipeptide antibody kindly provided by Dr. Douglas M. Stocco (Texas Tech University, Lubbock, TX) (8) and a polyclonal antibody raised against recombinant human StAR which will be described elsewhere.

Results

Sequencing of the StAR gene. All PCR products from the StAR gene were successfully amplified with the expected sizes. In kindred 1, we detected a homozygous nonsense mutation in the StAR gene. Direct sequencing of PCR products using primer pairs E and F revealed that a one base substitution of C to T changed CAG(Gln) at codon 258 in exon 7 to TAG (stop codon) (Fig. 3 B). In kindred 2, we detected the same C to T transition at codon 258 in one allele from each of the two siblings. In addition, these siblings bear a frame-shift mutation in the other allele in exon 6 caused by a single A base deletion out of three A bases at codon 238. The pedigree analysis revealed that the parents were heterozygous for either the Gln 258 Stop codon mutation or the single A deletion mutation (Fig. 4, A–C, and Fig. 5).

Functional studies. COS-1 cells transfected with the cholesterol side-chain cleavage system and wild-type StAR efficiently converted cholesterol into pregnenolone, but cotrans-



fection with either the pSV-SPORT-1 vector or the vector expressing the StAR protein resulting from the frame-shift due to the A deletion at codon 238 did not enhance the conversion of cholesterol to pregnenolone (Table I). Previously, we established that the Gln 258 Stop mutant protein is biologically inactive and did not therefore retest the functional activity of this mutant in the present study (8). Western blot analyses revealed that the 238 del A mutant protein was expressed at high levels in the COS-1 cells (Fig. 6). The mutant protein had a molecular weight greater than wild-type StAR, but also appeared to be processed to lower molecular weight species,

presumably reflecting cleavage of the mitochondrial import sequence after entry of the mutant StAR preprotein into the mitochondria.

Discussion

In this study, we identified a homozygous mutation of Gln 258 Stop in kindred 1 and a compound heterozygous mutation of Gln 258 Stop and single A deletion at codon 238 in kindred 2. In vitro coexpression studies of these StAR proteins with the cholesterol side-chain cleavage system in COS-1 cells demon-

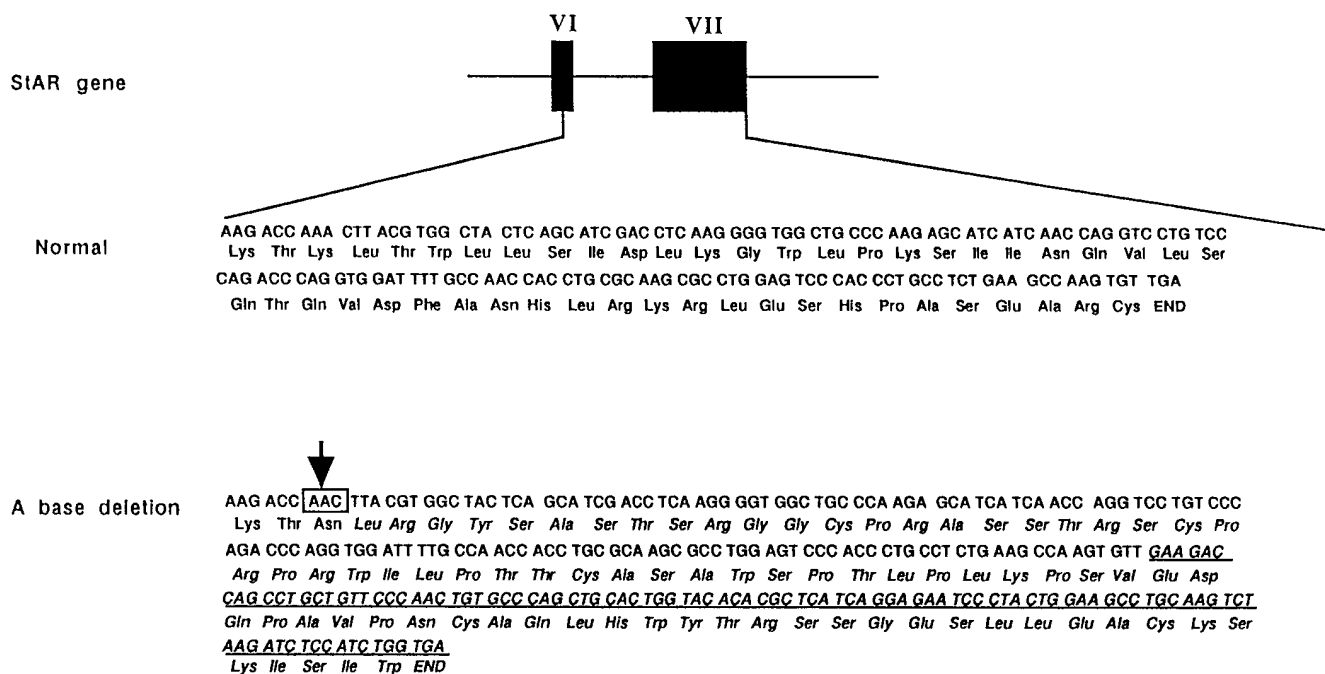


Figure 5. Schematic representation of the StAR gene and partial nucleotide sequence from codon 238 in the normal StAR gene and the gene bearing the frame-shift resulting from one A base deletion at codon 238. The partial predicted amino acid sequence encoding the normal and mutated StAR protein is also shown. Italics indicate the amino acids after codon 238. The underlining indicates the additional 34 amino acids in the mutant StAR protein. The arrow indicates the site of a single A deletion.

strated that the mutant proteins were devoid of steroidogenesis enhancing activity, establishing that these mutations cause lipoid CAH. The pedigree analysis in family 2 revealed that the father was heterozygous for the Gln 258 Stop codon mutation, while the mother was heterozygous for a single A deletion mutation, consistent with the autosomal recessive transmission of this disorder.

Although our patients have nonfunctional StAR proteins, they developed female secondary sexual characteristics and cyclical menstrual bleeding. Similar to our cases, three Japanese 46,XX patients with lipoid CAH have been reported to manifest female secondary sexual characteristics (12). We have also identified five additional cases of pubertal-aged 46,XX Japanese patients with lipoid CAH who manifested spontaneous puberty (13). How can this phenomenon be explained if StAR is essential for steroidogenesis in both the adrenal cortex and ovary? One possible explanation is that the amounts of chole-

sterol that are converted into steroid hormones in the adrenal gland, testes, and ovary are different. Serum concentrations of cortisol and testosterone are generally much higher than those of estradiol. To produce sufficient amounts of cortisol > 100 times greater quantities of cholesterol must undergo side-chain cleavage in the adrenal cortex than to produce the levels of estradiol found in the follicular phase. Thus, impairment of StAR protein function would profoundly affect steroidogenesis in adrenal glands, resulting in adrenal insufficiency. Quanti-

Table I. Functional Analysis of the StAR 238 del A Mutant

	Pregnenolone secretion
	ng/dish
pSPORT-1	8.3±1.2
pStAR	69.2±16.3
p238Ade1	6.7±0.5

COS-1 cells were transfected with a plasmid expressing the human cholesterol side-chain cleavage enzymes as a fusion protein and the indicated plasmids. Pregnenolone secreted into the culture medium was assayed by radioimmunoassay. Values presented are means±SE from three separate experiments.

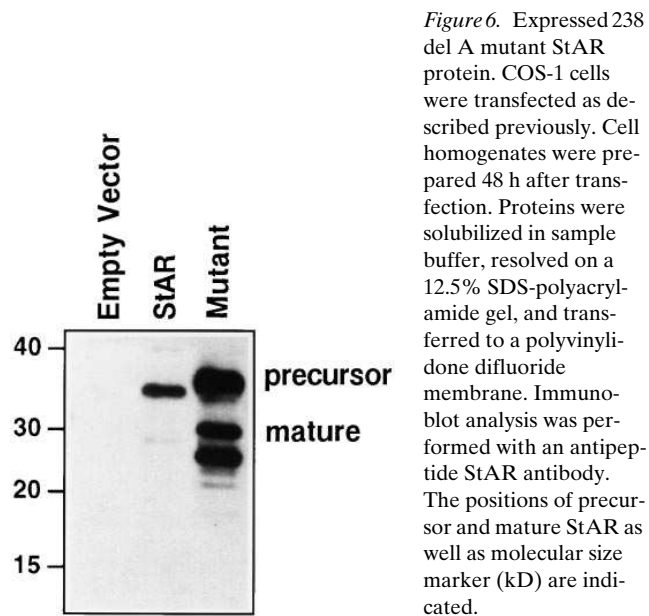


Figure 6. Expressed 238 del A mutant StAR protein. COS-1 cells were transfected as described previously. Cell homogenates were prepared 48 h after transfection. Proteins were solubilized in sample buffer, resolved on a 12.5% SDS-polyacrylamide gel, and transferred to a polyvinylidene difluoride membrane. Immunoblot analysis was performed with an antipeptide StAR antibody. The positions of precursor and mature StAR as well as molecular size marker (kD) are indicated.

ties of estradiol sufficient to promote pubertal changes and endometrial growth could be produced as a result of StAR-independent cholesterol translocation to the side-chain cleavage system. This notion is consistent with the fact that a small amount of pregnenolone is produced from cholesterol in coexpression studies in COS-1 cells in the absence of StAR (8). Peripheral conversion of androstenedione or testosterone to estradiol is unlikely in our patients, since these hormones were not detectable in blood.

The severe impairment of Leydig cell and adrenal cortex steroidogenesis that is apparent early in lipid CAH may result from the compounding effects of the massive accumulation of cholesterol and cholesterol esters in the cells, which is a hallmark of the disease. The stimulation of the adrenal and testicular cells in intrauterine life and in the newborn period renders these cells susceptible to cholesterol accumulation, which may compress cellular organelles and promote oxidative damage of the tissue. In contrast, the majority of follicular units in the ovary is dormant until puberty and only a small cadre is stimulated to grow at given times. Thus, the ovarian steroidogenic tissues are spared the early and persistent stimulation that dooms the testicular and adrenal cortical cells to damage from cholesterol engorgement. Alternatively, unlike the adrenal glands and testes, the ovaries might express a backup system for cholesterol transport into the mitochondria.

Despite the presence of sufficient amounts of estrogen to produce secondary sexual development and endometrial growth, progesterone levels remained undetectable in the subjects we studied. This suggests that the periodic vaginal bleeding was of an anovulatory nature or the result of ovulatory cycles with severely deficient luteal phases. The development of multiple cysts in the ovaries of the two subjects is consistent with the former possibility. Acyclic gonadotropin secretion with LH levels exceeding those of FSH and follicular cysts are characteristically observed in patients with polycystic ovary syndrome. However, in contrast to the usual subjects with this syndrome, who invariably have elevated ovarian androgen secretion, the females affected with lipid CAH had undetectable levels of androstenedione and testosterone. Hence, the pattern of gonadotropin secretion and the polycystic appearance of the ovaries cannot be attributed to hyperandrogenemia.

The 238 del A mutant lacks the normal StAR sequences in the COOH terminus as does the Gln 258 Stop mutant, which is prematurely truncated. The fact that these two different mutants yield nonfunctional proteins strongly suggests that COOH-terminal sequences in the StAR protein are essential for steroidogenic activity. The accumulation of the 238 del A mutant StAR protein in transfected COS-1 cells as well as evidence for processing of the mutant protein, presumably reflecting mitochondrial import, suggests that StAR's steroidogenic activity is not obligatorily linked to its entry into mitochondria and/or its subsequent proteolytic cleavage. This contrasts with the mechanism of StAR action proposed recently by Stocco and Clark (14). These authors suggested that the StAR preprotein is the active molecule and that its import into mitochondria is critical for its steroidogenesis-enhancing activity.

In summary, the two kindreds we have studied demonstrate the heterogeneity of the functional defects in gonadal steroidogenesis in lipid CAH. The novel 238 del A mutation

identified in one kindred also supports the notion that the COOH terminus of StAR is critical to its functional activity.

Acknowledgments

The authors thank Dr. Walter L. Miller (University of California, San Francisco) for providing the human cholesterol side-chain cleavage enzyme construct, Dr. Douglas M. Stocco (Texas Tech University) for providing anti-StAR antibody, and Dr. Charles A. Strott (National Institutes of Health) for providing the antiserum to pregnenolone used in these studies.

These studies were supported in part by Grants-in-Aid for Scientific Research from the Ministry of Education, Science, and Culture of Japan and a grant from the Investigation Committee on Abnormalities in Steroidogenesis from the Ministry of Health and Welfare of Japan and U.S. Public Health Service grant HD-06274 and National Cooperative Program for Infertility Research (HD 34449).

References

1. Miller, W.L. 1988. Molecular biology of steroid hormones synthesis. *Endocr. Rev.* 9:295-318.
2. Degenhart, H.J., K.H.A. Visser, H. Boon, and N.J.D. O'Doherty. 1972. Evidence for deficiency 20 α -cholesterol hydroxylase activity in adrenal tissue of a patient with lipid adrenal hyperplasia. *Acta Endocrinol.* 71:512-518.
3. Koizumi, S., S. Kyoya, T. Miyawaki, H. Kidani, T. Funabashi, H. Nakashima, Y. Nakamura, G. Ohta, E. Itagaki, and M. Katagiri. 1977. Cholesterol side-chain cleavage enzyme activity and cytochrome P450 content in adrenal mitochondria of a patient with congenital lipid adrenal hyperplasia (Prader disease). *Clin. Chim. Acta.* 77:301-306.
4. Hauffa, B.P., W.L. Miller, M.M. Grumbach, F.A. Conte, and S.L. Kaplan. 1985. Congenital adrenal hyperplasia due to deficient cholesterol side-chain cleavage activity (20,22 desmolase) in a patient treated for 18 years. *Clin. Endocrinol.* 23:481-496.
5. Lin, D., Y.J. Chang, J.F. Strauss III, and W.L. Miller. 1993. The human peripheral benzodiazepine receptor gene: cloning and characterization of alternative splicing in normal tissues and in a patient with congenital lipid adrenal hyperplasia. *Genomics.* 18:643-650.
6. Lin, D., S.E. Gitelman, P. Saenger, and W.L. Miller. 1991. Normal genes for the cholesterol side chain cleavage enzyme, P450_{scc}, in congenital lipid adrenal hyperplasia. *J. Clin. Invest.* 88:1955-1962.
7. Sakai, Y., T. Yanase, Y. Okabe, T. Hara, M.R. Waterman, R. Takayanagi, M. Haji, and H. Nawata. 1994. No mutations in cytochrome P450 side chain cleavage in a patient with congenital lipid adrenal hyperplasia. *J. Clin. Endocrinol. Metab.* 79:1198-1201.
8. Lin, D., T. Sugawara, J.F. Strauss III, B.J. Clark, D.M. Stocco, P. Saenger, A. Rogol, and W.L. Miller. 1995. Role of steroidogenesis acute regulatory protein in adrenal and gonadal steroidogenesis. *Science (Wash. DC)* 267:1828-1831.
9. Sugawara, T., J.A. Holt, D. Driscoll, J.F. Strauss III, D. Lin, W.L. Miller, D. Patterson, K.P. Clancy, I.M. Hart, B.J. Clark, and D.M. Stocco. 1995. Human steroidogenic acute regulatory protein: functional activity in COS-1 cells, tissue-specific expression, and mapping of the structural gene 8p11.2 and a pseudogene to chromosome 13. *Proc. Natl. Acad. Sci. USA.* 92:4778-4782.
10. Sugawara, T., D. Lin, J.A. Holt, W.L. Miller, and J.F. Strauss III. 1995. Structure of the human steroidogenic acute regulatory protein (StAR) gene: StAR stimulates mitochondrial cholesterol 27-hydroxylase activity. *Biochemistry.* 34:12506-12512.
11. Tee, M.-K., D. Lin, T. Sugawara, J.A. Holt, Y. Guiguen, B. Buckingham, J.F. Strauss III, and W.L. Miller. 1995. T \rightarrow A transition 11 bp from a splice acceptor site in the human gene for steroidogenic acute regulatory protein causes congenital lipid adrenal hyperplasia. *Hum. Mol. Genet.* 4:2299-2306.
12. Tanae, A., Y. Miki, and I. Hibi. 1988. Pubertal presentation in patients with congenital lipid adrenal hyperplasia (Prader's syndrome). *Acta. Paediatr. Jpn.* 30(Suppl.):236-238.
13. Nakae, J., T. Tajima, T. Sugawara, K. Hanakai, T. Hotsubo, N. Igarashi, Y. Igarashi, T. Ishii, N. Koda, T. Kondo, et al. 1997. Analysis of the steroidogenic acute regulatory protein (StAR) gene in Japanese patients with congenital lipid adrenal hyperplasia: functional implications. *Hum. Mol. Genet.* In press.
14. Stocco, D.M., and B.J. Clark. 1996. Regulation of the acute production of steroids in steroidogenesis. *Endocr. Rev.* 17:221-224.