JCI The Journal of Clinical Investigation

Central conducting lymphatic anomaly: from bench to bedside

Luciana Daniela Garlisi Torales, Benjamin A. Sempowski, Georgia L. Krikorian, Kristina M. Woodis, Scott M. Paulissen, Christopher L. Smith, Sarah E. Sheppard

J Clin Invest. 2024;134(8):e172839. https://doi.org/10.1172/JCI172839.

Review Series

Central conducting lymphatic anomaly (CCLA) is a complex lymphatic anomaly characterized by abnormalities of the central lymphatics and may present with nonimmune fetal hydrops, chylothorax, chylous ascites, or lymphedema. CCLA has historically been difficult to diagnose and treat; however, recent advances in imaging, such as dynamic contrast magnetic resonance lymphangiography, and in genomics, such as deep sequencing and utilization of cell-free DNA, have improved diagnosis and refined both genotype and phenotype. Furthermore, in vitro and in vivo models have confirmed genetic causes of CCLA, defined the underlying pathogenesis, and facilitated personalized medicine to improve outcomes. Basic, translational, and clinical science are essential for a bedside-to-bench and back approach for CCLA.

Find the latest version:

https://jci.me/172839/pdf

Central conducting lymphatic anomaly: from bench to bedside

Luciana Daniela Garlisi Torales,[1] Benjamin A. Sempowski,[1] Georgia L. Krikorian,[1] Kristina M. Woodis,[1] Scott M. Paulissen,[1] Christopher L. Smith,[2] and Sarah E. Sheppard[1]

[1]Unit on Vascular Malformations, Division of Intramural Research, *Eunice Kennedy Shriver* National Institute of Child Health and Human Development, NIH, Bethesda, Maryland, USA. [2]Division of Cardiology, Jill and Mark Fishman Center for Lymphatic Disorders, Children's Hospital of Philadelphia, Philadelphia, Pennsylvania, USA.

Central conducting lymphatic anomaly (CCLA) is a complex lymphatic anomaly characterized by abnormalities of the central lymphatics and may present with nonimmune fetal hydrops, chylothorax, chylous ascites, or lymphedema. CCLA has historically been difficult to diagnose and treat; however, recent advances in imaging, such as dynamic contrast magnetic resonance lymphangiography, and in genomics, such as deep sequencing and utilization of cell-free DNA, have improved diagnosis and refined both genotype and phenotype. Furthermore, in vitro and in vivo models have confirmed genetic causes of CCLA, defined the underlying pathogenesis, and facilitated personalized medicine to improve outcomes. Basic, translational, and clinical science are essential for a bedside-to-bench and back approach for CCLA.

Introduction

The lymphatic system and its functions. The lymphatic system is a network of vessels and associated organs that play an essential role in human health by maintaining human tissue fluid homeostasis, transporting immune cells, and absorbing dietary lipids (Figure 1A) (1). Lymphatic vessels transport interstitial fluid reabsorbed from tissues along with antigens and leukocytes destined for the lymph nodes that are then transferred to the blood. Lymphatic vasculature plays an important role in the gastrointestinal system, where peripheral lymphatics transport chyle, a mixture of lymph and chylomicrons broken down from dietary lipids to the thoracic duct (1–3). The meninges of the central nervous system also contain a vast network of lymphatic vessels that participate in the transportation of cerebrospinal fluid out of the brain (4, 5). In cases of human disease, the lymphatic system plays essential roles in regulating tissue pressure, immune surveillance, and energy regulation and has been implicated in chronic inflammation and cancer (1–3).

Molecular studies have demonstrated the role of specific signaling pathways in lymphatic development (Figure 1B). VEGF-C and its receptor VEGFR3 (also known as FLT4) are essential for lymphangiogenesis, the sprouting growth of lymphatic vessels. VEGFC signaling requires collagen- and calcium-binding EGF domains 1 (CCBE1) and ADAMTS3 for proteolytic cleavage (6–10). VEGFC/VEGFR3 signaling occurs through Erk to induce cell-cycle arrest and regulate lymphangiogenesis (11, 12). Molecular programs also direct the formation and maintenance of lymphatic valves — many of which also have been implicated in human disease. For example, FOXC2 along with flow activates connexin-37 (CX37) and calcineurin/NFATC signaling (13). GATA2, integrin-alpha9, ephrinB2/Ephb4 signaling, VE-cadherin, Foxo1, and Piezo1 all regulate valve formation and maintenance (14–23). Furthermore, disease models inducing overactivation of Ras signaling demonstrate valvular dysfunction (24).

The main structural components of the lymphatic system are lymphatic capillaries, lymphatic afferent and efferent vessels, lymph nodes, and lymphoid organs including the tonsils, thymus, spleen, and bone marrow (25). Lymphatic endothelial cells (LECs) constitute the most basic level of the lymphatic system and form the core lymphatic structures. LECs have both venous and nonvenous origins. They initially emerge from embryonic veins and are subsequently organized into lymphatic structures (6, 26–33). Among LECs, those of venous origin are thought to be the major contributors to the lymphatic vasculature (30–38). However, nonvenous origins have been demonstrated in organ-specific lymphatics, such as the mesentery (39), heart (40), and skin (41), including hemogenic endothelium (derived from the blood vasculature) contributing to dermal lymphatics (42). Lymphatic capillaries form interfaces with arteriovenous capillary beds throughout the body in a peripheral plexus (Figure 1C). This plexus is characterized by LECs with button junctions and a discontinuous basement membrane (BM) and blind-ended sacs that allow for the exchange of lipids, proteins, and water, as well as pathogens and immune cells. Lymphatic capillaries drain into precollecting lymphatics, then collecting lymphatic vessels, to the thoracic duct and the right lymphatic duct, and finally to the venous system. The collecting lymphatics are lined with endothelial cells that have zipper-like junctions and are encased in perivascular smooth muscle cells that contract to propel lymph forward and valves to prevent backflow of lymph. In humans, the central lymphatics include the cisterna chyli — where the lower extremity peripheral lymphatics and intra-abdominal lymphatics

Conflict of interest: The authors have declared that no conflict of interest exists.
Copyright: © 2024, Garlisi Torales et al. This is an open access article published under the terms of the Creative Commons Attribution 4.0 International License.
Reference information: *J Clin Invest*. 2024;134(8):e172839. https://doi.org/10.1172/JCI172839.

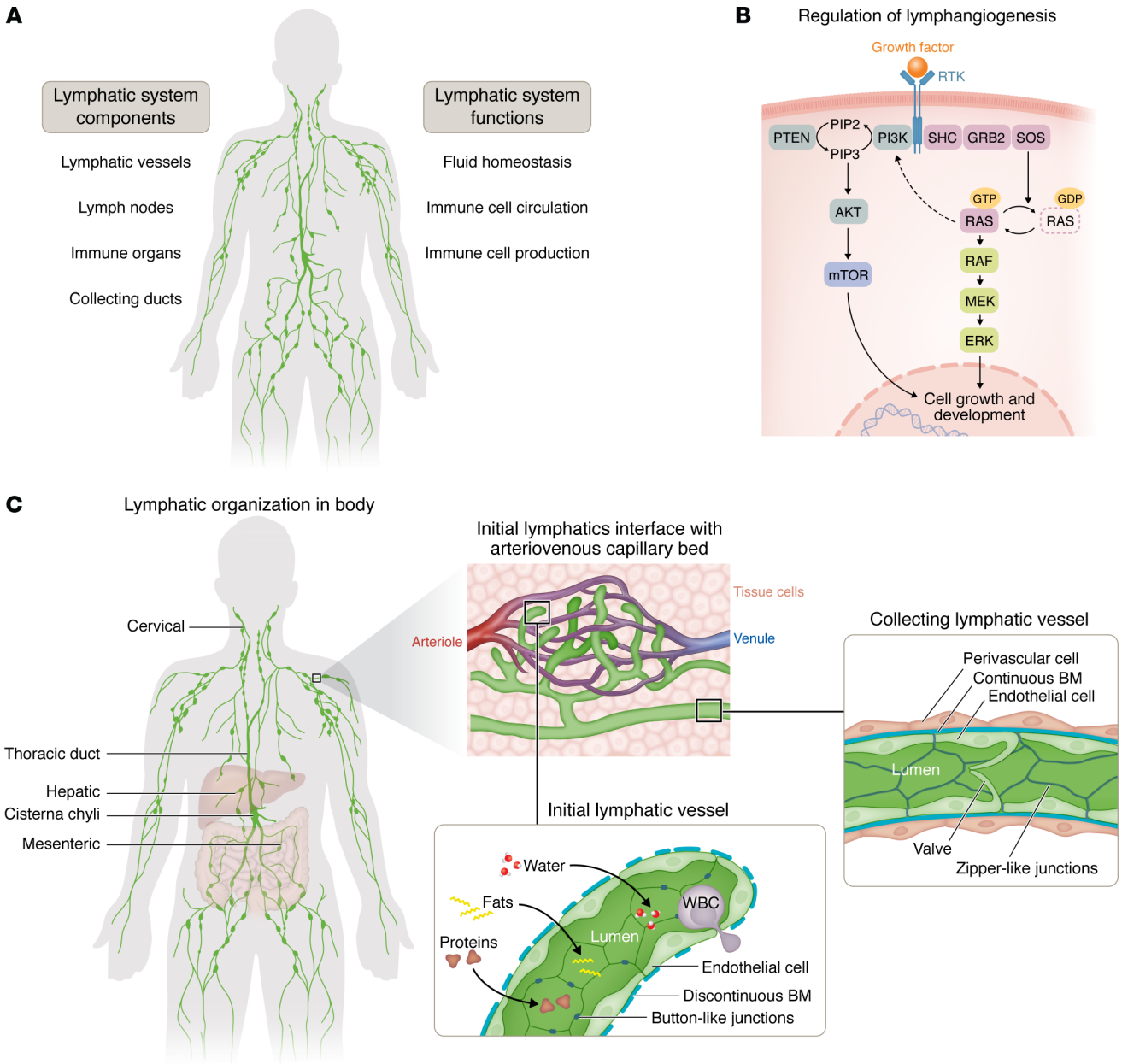

Figure 1. Overview of the lymphatic system and lymphangiogenesis. (**A**) Components and functions of the lymphatic system. (**B**) Schematic showing the major growth factor signaling pathways. Pathogenic variants in receptor tyrosine kinases, components of PI3K signaling, and components of RAS/MAPK signaling are important drivers of vascular anomalies. (**C**) Schematic showing the lymphatic system at the vascular level with important structures and interactions with the venous and arterial systems.

converge to a central drainage channel — and the thoracic duct (43). Disorders involving the central lymphatics may be seen in complex lymphatic anomalies (3, 44–49).

Complex lymphatic anomalies. Complex lymphatic anomalies (CLAs) are a group of overlapping disorders of diffuse lymphatic malformations caused by pathogenic variants (previously known as genetic mutations) (3, 44–48). These include central conducting lymphatic anomaly (CCLA), which also can be known as channel type lymphatic malformation, generalized lymphatic anomaly (GLA), kaposiform lymphangiomatosis (KLA), and Gorham-Stout disease (GSD). CCLA is a heterogenous disorder characterized by abnormal conduction through the central lymphatics (46). GLA is characterized by the invasion of lymphatic vessels into organs, such as the spleen, medullary bone, and the surrounding soft tissue due to the abnormal proliferation of LECs (49). KLA has some phenotypic overlap with GLA but is defined by the unique spindle-shaped morphology of affected LECs on biopsy (49–51). Mediastinal involvement as well as pericardial effusions may also be prevalent (52). KLA has a high morbidity due to the severity of the lesions (53). GSD, also known as vanishing bone disease, involves the spontaneous reabsorption of cortical bone due to the hyperproliferation of surrounding lymphatic vessels (54–56). It is important to note that all CLAs may have a degree of abnormal central lymphatic conduction (57–60).

Central conducting lymphatic anomaly. CCLA is one of the most heterogeneous types of CLA, as it encompasses any anomaly or dysfunction affecting the central lymphatic channels (thoracic duct and/or the cisterna chyli), which may become dilated, tortuous, or leaky. CCLA can be further classified as primary, with lymphatic dysfunction identified as the primary malformation, sometimes due to an identifiable genetic cause; or secondary, with lymphatic dysfunction acquired due to high central venous pressures or traumatic leaks (61, 62). Individuals affected by CCLA may present with nonimmune fetal hydrops, pleural effusions, ascites, anasarca, protein-losing enteropathy, plastic bronchitis, pulmonary lymphatic perfusion, and even lymphedema (44, 61, 63–65). These symptoms can be severely debilitating and even lead to death.

CCLA lacks concrete diagnostic criteria, and there is limited availability of central lymphatic imaging, which leaves some affected individuals with a symptomatic diagnosis (e.g., chylous ascites). CCLA can be found as a feature of multiple syndromes as well as an isolated disorder due to somatic genetic causes. Further research is needed to differentiate whether the genetic causes associated with CCLA (single-gene syndromes, mosaic somatic pathogenic mutations, aneuploidy, etc.) have disparate or similar underlying pathogenic mechanisms.

There is a profound need for continued basic and translational investigations to improve the lives of individuals with CCLA. The goal of this Review is to summarize the basic science that has led to clinical advances in CCLA. To do this, we first highlight the advances in imaging and molecular genetics that have resulted in improved diagnosis of CCLA. Next, we review the in vitro and in vivo models that have advanced our understanding of the cellular and molecular mechanisms underlying CCLA and advanced drug repurposing strategies. We conclude with a brief discussion of the human case studies using targeted pathway inhibitors for improved outcomes in individuals with CCLA.

Advances in lymphatic system imaging enhance CCLA diagnosis

As the knowledge base about the flow and function of the lymphatic system grows, diagnostic options have improved with the development of more-effective methods for imaging the lymphatic system. Traditional MRI may visualize aspects of the lymphatic system such as the thoracic duct, but it fails to characterize flow and function of the central lymphatic vasculature (66). Some radiologists found success with these techniques, but only under very specific positional and clinical circumstances (67). However, the combination of contrasted MRI with angiography techniques has led to a new imaging technique for the study of the lymphatic system.

Dynamic contrast-enhanced magnetic resonance lymphangiography (DCMRL) is essential for the diagnosis of lymphatic conduction disorders (68). This allows for dedicated visualization of central lymphatic flow (63, 69–73). The feasibility of DCMRL was initially studied in a porcine model due to the structural homology of their central lymphatic system to that of humans (71, 74). These studies found no adverse effects of intradermal or intranodal injection of contrast with subsequent DCMRL imaging and were able to clearly visualize central lymphatic structures such as the thoracic duct (71, 74).

The technique has been developed using three different approaches: intranodal (IN), intrahepatic (IH), and intramesenteric (IM) (Figure 2A). Researchers found that IN contrast injection allows for more-localized visualization of the lymphatic system and may be more appropriate in pediatric individuals compared with the more elaborate conventional lymphangiography (72, 75). For the investigation of IH lymphatic flow disorders, DCMRL was identified as an effective method for visualization of lymphatic flow in and around the liver, including the cisterna chyli (76). IM DCMRL was identified as a superior method for identifying peritoneal and duodenal leaks compared with the IN and IH approaches, indicating that it is more efficacious in the diagnosis and treatment of CCLA with these features (77). DCMRL can be performed from any lymph node access point to assist in the diagnosis of conduction issues, such as in one case study of an individual with GSD (78).

Evaluation of central lymphatic flow patterns demonstrated distinct features in individuals with various genetic disorders, such as RASopathies, Down syndrome (trisomy of chromosome 21), and *PIEZO1* generalized lymphatic dysplasia (Figure 2, B–D). RASopathies, which include Noonan syndrome, tend to have abnormalities of the thoracic duct and intercostal flow (61, 79–81). Individuals with Down syndrome have dilation of the lymphatics of the head and neck (61). Characteristic imaging findings in individuals with *PIEZO1*–generalized lymphatic dysplasia include connections between the hepatic and peribronchial lymphatics (61). Importantly, if genetic testing is negative or unavailable, the abnormal lymphatic flow patterns identified by DCMRL may hint at genetic diagnosis and possibly guide medical treatment. While not yet widely available, DCMRL is a useful tool in the diagnosis of CCLA and may facilitate interventions. The Lymphatic Education and Research Network maintains a list of Comprehensive Centers of Excellence (https://lymphaticnetwork.org/centers-of-excellence), many which offer DCMRL.

State-of-the-art genetic advances facilitate identification of genetic causes

The advent of deep sequencing has allowed for identification of the genetic causes of CCLA. Notably, identification of the genetic cause can help refine clinical diagnosis and provide important information about the underlying pathophysiology as well as directing medical therapy. Genetic sequencing can be performed from either genomic DNA or cell-free DNA (cfDNA). Initial retrospective cohort studies demonstrated that about 25% of individuals with primary CCLA have a cause that can be identified from clinical genetic testing (61). More recent work suggests this rate may increase up to about 40% by use of a comprehensive sequencing approach and novel techniques (48). In secondary CCLA, usually no genetic cause is identified (48).

Genetic causes of CCLA may be germline or somatic. Germline genetic cause can easily be discovered from leukocyte genomic DNA isolated from either a saliva or blood sample. Somatic causes must be identified from an affected tissue source, which often can be complicated in CCLA. Recent work demonstrated that ultra-deep sequencing using unique molecular identifiers and cfDNA isolated from blood or lymphatic fluid can identify causative variants in CCLA (48). Clinically discarded

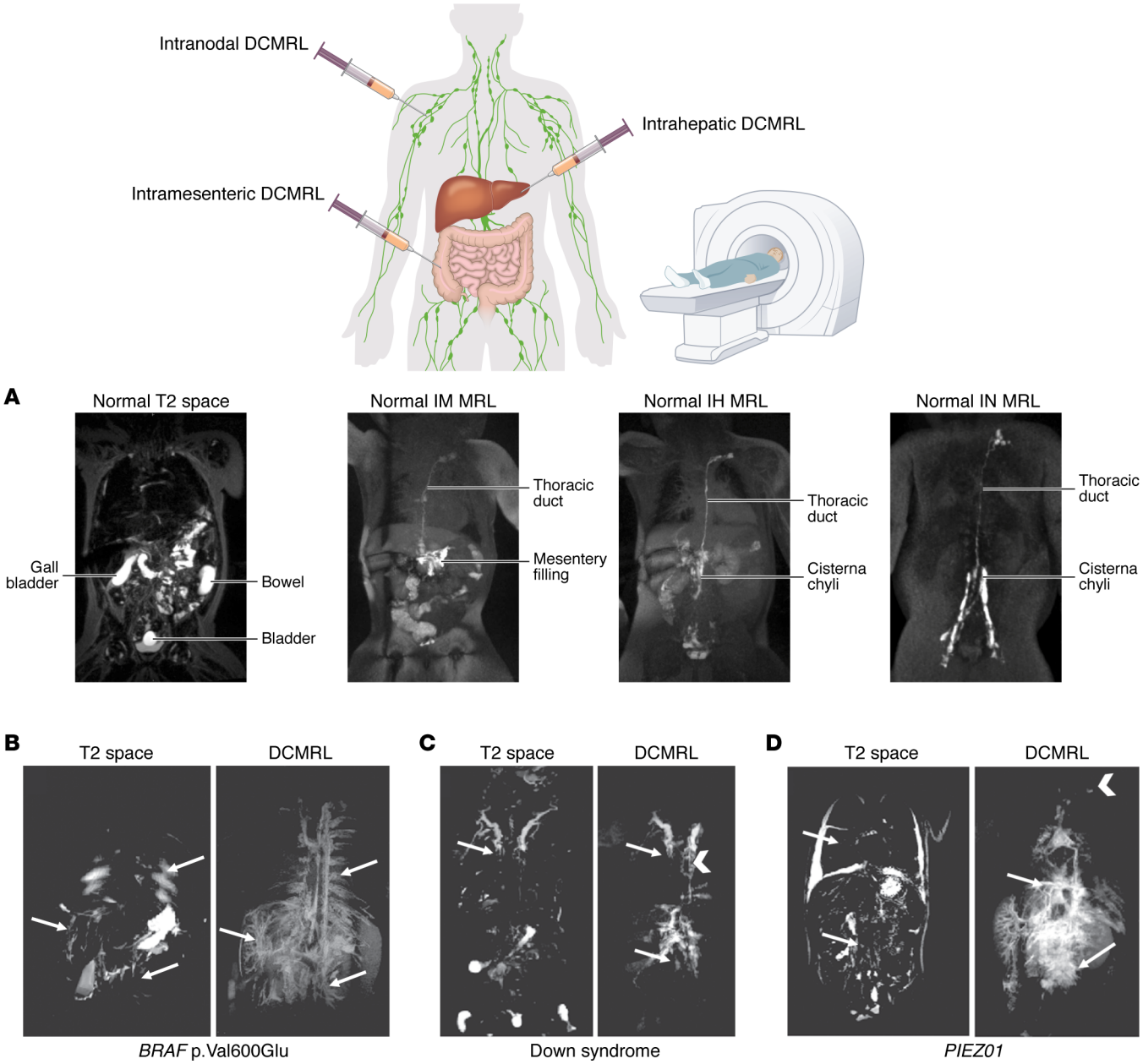

Figure 2. Schematic of the various DCMRL approaches. DCMRL can be performed using contrast that is injected into a lymph node, liver, and/or mesentery. Traditional T2 space MRI and DCMRL imaging representing the typical appearance of the lymphatic vessels (**A**) compared with their appearance in three individuals with CCLA due to mosaic *BRAF* (**B**), Down syndrome (**C**), and *PIEZO1*–generalized lymphatic dysplasia (**D**). In **B**, mosaic *BRAF* p.Val600Glu, T2 space imaging shows substantial edema in the intercostal, mesentery, and liver lymphatics that correlates with abnormal perfusion patterns on intrahepatic DCMRL. Also note the abnormal lymphatic thoracic vessels lacking a normal thoracic duct. In **C**, Down syndrome, T2 space imaging shows edema in the supraclavicular (and superior mediastinal) lymphatics (arrows). On intrahepatic DCMRL, there is retrograde flow into retroperitoneal lymphatics and intercostal, mediastinal, pulmonary, and supraclavicular perfusion (arrows). Arrowhead indicates a patent thoracic duct that courses to the left venous angle. In **D**, *PIEZO1*–generalized lymphatic dysplasia, T2 space imaging shows bilateral pleural effusions, and pulmonary and retroperitoneal edema (arrows). Intrahepatic DCMRL shows extensive flow to the hepatic capsular lymphatics, with extension into the mediastinum and pulmonary lymphatics (arrows). There is also retrograde flow into the retroperitoneal lumbar and mesenteric lymphatics. The arrowhead indicates a small thoracic duct coursing to the left venous angle, patent on follow-up imaging. IM, intramesenteric; IH, intrahepatic; IN, intranodal. Images reproduced from ref. 61 with permission.

samples, such as pleural fluid, were processed to enrich for endothelial cells using centrifugation, endothelial cell–specific cell culture conditions, and CD31 magnetic bead enrichment (48). These endothelial cells constituted an affected tissue sample that then was processed for sequencing.

These techniques have allowed researchers to identify single-gene disorders causing CCLA (Table 1). Mosaic and germline RASopathies due to pathogenic variants that result in upregulation of the RAS/MAPK signaling pathway are the most common causes of CCLA (Figure 1B) (48, 61, 80–88). Specifically, somatic

Table 1. Human genetics of CCLA

	Syndrome or clinical phenotype	Inheritance	Number of individuals	Reference
Gene				
EPHB4	Capillary malformation–arteriovenous malformation syndrome, CCLA, varicose veins	Autosomal dominant	1	Li et al. 2018 (94)
ARAF	CCLA and lymphedema	Somatic, autosomal dominant	2	Li et al. 2019 (82)
JAG1	Alagille syndrome	Autosomal dominant	1	Li, Sheppard, et al. 2021 (96)
PTPN11	Noonan syndrome	Autosomal dominant	21	Liu et al. 2022 (61); Li, Sheppard, et al. 2023 (48); Kleimeier et al. 2022 (80); Pieper et al. 2022 (81); Nakano et al. 2022 (86); Pham et al. 2020 (87)
HRAS	Costello syndrome	Autosomal dominant	1	Liu et al. 2022 (61)
RIT1	Noonan syndrome	Autosomal dominant	13	Liu et al. 2022 (61); Li, Sheppard, et al. 2023 (48); Kleimeier et al. 2022 (80); Liu and Gao 2022 (142); Pieper et al. 2022 (81); Gordon et al. 2022 (84); Nakano et al. 2022 (86); Hribernik et al. 2023 (141)
SOS1	Noonan syndrome	Autosomal dominant	4	Dori et al. 2020 (83); Kleimeier et al. 2022 (80); Nakano et al. 2022 (86); Lioncino et al. 2022 (140)
SOS2	Noonan syndrome	Autosomal dominant	4	Li, Sheppard, et al. 2023 (48); Kleimeier et al. 2022 (80)
RASA1	CCLA, capillary malformation–arteriovenous malformation syndrome	Autosomal dominant	2	Li, Sheppard, et al. 2023 (48); Mologousis et al. 2023 (88)
KRAS	Lymphedema and CCLA; oculoectodermal syndrome, encephalocraniocutaneous syndrome, nevus sebaceous syndrome; Noonan syndrome, cardiofaciocutaneous syndrome; isolated CCLA	Somatic, autosomal dominant	8	Sheppard et al. 2023 (85); Li, Sheppard, et al. 2023 (48); Liu et al. 2022 (61); Pieper et al. 2022 (81)
BRAF	Noonan syndrome, cardiofaciocutaneous syndrome; isolated CCLA	Somatic, autosomal dominant, mosaic	4	Li, Sheppard, et al. 2023 (48); Liu et al. 2022 (61); Gordon et al. 2022 (84)
RAF1	Noonan syndrome	Autosomal dominant	2	Li, Sheppard, et al. 2023 (48)
MDFIC	CCLA and lymphedema	Autosomal recessive	7	Byrne et al. 2022 (95)
PIEZO1	*PIEZO1*–generalized lymphatic dysplasia	Autosomal recessive	2	Liu et al. 2022 (61)
GBA	Gaucher disease	Autosomal recessive	1	Liu et al. 2022 (61)
GBE1	Andersen disease	Autosomal recessive	1	Liu et al. 2022 (61)
FOXC2	Lymphedema-distichiasis syndrome	Autosomal dominant	2	Liu et al. 2022 (61); Li, Sheppard, et al. 2023 (48)
MAP2K1	Capillary malformation, lateralized overgrowth, chylous pericardial effusion, CCLA	Somatic	1	Li, Sheppard, et al. 2023 (48)
GNA11[A]	Reticulated capillary malformation, CCLA	Somatic	1	Li, Sheppard, et al. 2023 (48)
NF1[B]	Neurofibromatosis	Autosomal dominant	1	Li, Sheppard, et al. 2023 (48)
PIK3CA	*PIK3CA*-related vascular malformations	Somatic	4	Li, Sheppard, et al. 2023 (48); Grenier et al. 2023 (97)
Chromosomal abnormality				
Trisomy of chromosome 21[C]	Down syndrome	N/A	7	Liu et al. 2022 (61); Li, Sheppard, et al. 2023 (48)
22q11.2 deletion	22q11.2 deletion syndrome	Autosomal dominant	2	Liu et al. 2022 (61)
Heterozygous 4q28.3q32.3 duplication[D]	Craniosynostosis, developmental delay, atypical facial features, CCLA	Autosomal dominant	1	Traub et al. 2021 (98)

Some larger cohort studies have included affected individuals previously published, which has been incorporated into the table. Only genes with pathogenic or likely pathogenic variants are included. Variants of uncertain significance (VUSs) have been reported in *LZTR1*, *FAT4*, and *RASA1* (48, 61). Three additional individuals have been reported with clinical diagnoses of Noonan syndrome (143–145). [A]The individual also has diagnosis of Down syndrome. [B]Listed as secondary CCLA; primary CCLA cannot be ruled out given the gene is involved in the RAS/MAPK pathway. [C]One individual also had a recurrent, somatic GNA11 pathogenic variant. [D]No somatic testing performed.

pathogenic variants in *ARAF*, *BRAF*, *KRAS*, and *MAP2K1* resulting in isolated lymphatic as well as syndromic presentations have been identified (48, 61, 82, 85). Germline monoallelic pathogenic variants in *PTPN11*, *KRAS*, *HRAS*, *BRAF*, *RAF1*, *RIT1*, *SOS1*, *SOS2*, and *RASA1* have been identified in individuals with CCLA and Noonan syndrome, CCLA and Costello syndrome, CCLA and cardiofaciocutaneous syndrome, or CCLA and capillary malformation-arteriovenous malformation syndrome (48, 61, 80–88). Interestingly, the phenotypic heterogeneity may be due to second hits, as has been demonstrated in *RASA1* disorders (89–93). Other single-gene causes that have been described include *PIEZO1*, *FOXC2*, *EPHB4*, *MDFIC*, *JAG1*, *PIK3CA*, *GBA*, and *GBE1* (48, 61, 94–97). *GNA11* was identified as a potential candidate gene, but functional studies are needed (48).

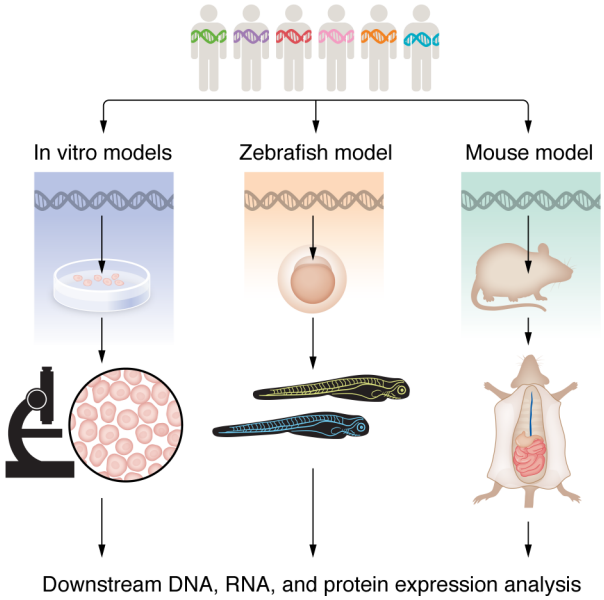

Figure 3. Overview of preclinical models of CCLA. Various in vitro models can be used to investigate cell-specific gene expression, endothelial migration, barrier formation, and cell proliferation. Utilization of the zebrafish to express affected individual–specific gene variants can be used for fluorescence imaging of the lymphatics and pharmaceutical screening. The murine model allows for a more in-depth tissue analysis of lymphatic vessels in mutant models of affected individual–specific variants and for targeted drug evaluation.

Chromosomal disorders have also been identified in connection with CCLA (Table 1). The most common is Down syndrome, caused by the presence of an additional chromosome 21 (61). 22q11.2 deletion syndrome, previously known as velocardiofacial syndrome, has been identified in individuals with CCLA (61). A chromosome 4 duplication was previously described in an individual with CCLA; however, no somatic testing was performed (98).

These research advances and the body of knowledge that has grown about the genetic causes of CCLA suggest that all individuals with CCLA should undergo clinical genetic testing. Clinically available genetic diagnostic tests are gene panels, exome sequencing, and genome sequencing from genomic DNA isolated from leukocytes or other tissues (99). One limitation of gene panels is that they are only useful in the diagnosis of known genetic causes (100). Exome sequencing will identify variants in the protein-coding areas of DNA, whereas genome sequencing includes both coding and noncoding areas of DNA, though at lower coverage than exome sequencing. The methods chosen should be targeted to the individual's characteristics. Clinical development of vascular anomaly–specific cfDNA and lymphatic fluid–based tests will provide a noninvasive method for somatic testing when affected tissue is not readily available for testing (48). Furthermore, evaluation of the utility of long-read genome sequencing may identify novel causes.

Preclinical models enable personalized medicine approaches

Investigation of the mechanisms underlying CCLA and validation of candidate genes hinges on effective in vitro and in vivo preclinical models to study lymphatic development and disease (Figure 3). In vitro models allow for efficient characterization of cellular behavior and molecular mechanisms (101). Vertebrate models such as zebrafish and mice can more effectively model physical anomalies and monitor phenotypes (101). Importantly, current models may help us identify novel human disease genes or validate candidate human disease genes. For rare diseases such as CCLA that do not have an effective treatment, these models can also allow for pharmaceutical safety and efficacy testing, leading to novel therapeutics for affected individuals.

In vitro models of CCLA. In vitro models using primary or derived human cell lines allow for more rapid investigation of the cellular and molecular mechanisms behind CCLA (Figure 3 and Table 2). Viral vectors allow for the transfection of aberrant proteins of interest into cell lines for downstream analysis of cellular mechanisms. Coupled with cell-specific assays, these allow for the investigation of the cellular mechanisms behind CCLA.

To investigate human-specific pathogenic variants in *MDFIC* (MyoD family inhibitor domain–containing protein), an autosomal recessive candidate gene for CCLA, researchers used primary adult human dermal LECs (HDLECs) and HEK293T cells (95). siRNA knockdown of MDFIC in HDLECs resulted in increased adhesion and decreased migration compared with controls. Ectopic expression of participants' variants in HEK293T cells demonstrated truncation of the MDFIC p.M131fs* protein and that the truncated protein was not present at the cell surface. Furthermore, coexpression of MDFIC with GATA2 in HEK293T cells showed that the mutant protein did interact with GATA2, which plays an essential role in lymphatic development and maintenance. Overall, using a combination of different cells and traditional techniques such as immunoblotting, FACS, immunoprecipitation, adhesion, and migration assays, the researchers were able to define the cellular behavior of the mutant MDFIC.

RASopathy-associated pathogenic variants result in cellular defects as well as increased lymphangiogenesis. To evaluate this, researchers transduced mutant proteins of interest into HDLECs, followed by immunostaining for cytoskeletal proteins or conducting a spheroid sprouting assay (48, 82, 85). Expression of mutant ARAF protein led to increased internalization of VE-cadherin, abnormal actin cytoskeleton, and elongation of the cells, which was improved by trametinib treatment. Similar results were seen with expression of mutant KRAS proteins. Spheroid models are also an effective three-dimensional method for evaluating the effect of a variant on lymphangiogenesis (Figure 4A) (48, 82, 85). These assays demonstrated increased sprouting behavior, including cumulative sprout length and number of sprouts per sphere in *ARAF*, *KRAS*, *BRAF*, and *RAF1* models, which was also reduced with trametinib (48, 82, 85). Additionally, lysates from spheroid models can be used in typical biochemical assays and demonstrated increased ERK phosphorylation at Thr202/Tyr204, which was inhibited by trametinib (48, 82, 85).

More-advanced techniques such as "organ on a chip" will allow for affected-individual specific cellular models that can mimic in vivo assays (102–104). Although previous work used isolated endothelial cells from individuals with CCLA for genomic

Table 2. Cellular models of CCLA

Gene and identified variant	Protein function	Association with human disease	Cellular model used	Application of model	Reference
EPHB4; c.2334 + 1G>C	Receptor tyrosine kinase	CM-AVM, CCLA, LMs	Transfection of variants into HEK293T and A375 cell lines	Immunoprecipitation assays, Western blotting, DNA sequencing, and CRISPR/Cas9 precision editing	Li et al. 2018 (94)
ARAF; p.Ser214Pro	RAF kinase in MAPK signaling	Proto-oncogene, CCLA, RASopathies	Transfection of variant into HeLa cells and HDLECs; spheroid culture with HDLECs	Western blotting, sprouting assay, and pharmaceutical screening	Li et al. 2019 (82)
KRAS; p.Gly12Asp, p.Gly13Asp, p.Ala146Thr	RAS-GTPase in MAPK signaling	CCLA, LMs, RASopathies, proto-oncogene, AVMs, GSD, KLA, GLA	Transfection of variant into HDLECs	Western blotting, qRT-PCR, immunofluorescence staining, sprouting assays, and pharmaceutical screening	Sheppard et al. 2023 (85); Li, Sheppard, et al. 2023 (48)
BRAF; p.Phe486Ser	RAF kinase in MAPK signaling	Proto-oncogene, CCLA, RASopathies	Transfection of variant into HDLECs	Organoid sprouting assay	Li, Sheppard, et al. 2023 (48)
RAF1; p.Thr145Pro	RAF kinase in MAPK signaling	Proto-oncogene, CCLA, RASopathies	Transfection of variant into HDLECs	Organoid sprouting assay	Li, Sheppard, et al. 2023 (48)
MDFIC; p.Met131Asnfs*3, p.Phe244Leu, p.Ser124*, p.Gly63*	MyoD family inhibitor domain–containing protein	CCLA, lymphedema	Ectopic expression of variants in lymphatic endothelial, HeLa, and HEK293T cell lines	Migration assays, protein expression analysis, flow cytometry localization assays, and pharmaceutical screening	Byrne et al. 2022 (95)

AVM, arteriovenous malformation. LM, lymphatic malformation.

analysis, some studies have isolated LECs from other lymphatic malformations and cultured these for downstream analysis (48, 105, 106). In combination with organ-on-a-chip models, this could facilitate investigations of mechanisms such as endothelial cell adhesion, membrane permeability, and fluid dynamics and personalized therapeutic approaches, benefitting individuals without an identifiable genetic cause (102–104).

Zebrafish as a model for CCLA. Zebrafish are a well-established model for developmental biology and have been an increasingly popular model organism of choice for vascular and lymphatic researchers since the characterization of the developing zebrafish lymphatic system (Figure 3) (6, 107–111). They are optically clear and externally fertilized, which allows for high-resolution analysis of developmental processes in living specimens. Augmenting the value of zebrafish in live imaging is the availability of an expansive collection of fluorescent marker lines, making imaging and identification of developing structures much easier (27, 110, 112, 113). Additionally, zebrafish yield fantastic opportunities for molecular investigation because they are highly manipulatable, have excellent genetic conservation, and have comparatively high fecundity, which allows for rapid and high-throughput pharmaceutical screening. Finally, zebrafish have striking morphological similarity to humans, including the presence of the thoracic duct, which models the thoracic duct in humans. With these characteristics taken together, zebrafish are an effective model to examine phenotype and developmental changes.

There are multiple methods available to model specific variants in the zebrafish (113). Loss-of-function variants can be modeled using CRISPR/Cas9 to decrease in the activity of the protein of interest. Although morpholinos (MOs) are still occasionally used for gene knockdown, mutant phenotypes may not be congruent with MO phenotypes (114). Gain-of-function variants can be expressed throughout the embryo or in a cell type–specific manner by either mRNA injection or the Tol2 transposase system (115, 116). Following a bedside-to-bench or forward-genetics workflow, pathogenic variants or variants of uncertain significance can first be identified in individuals affected by CCLA. Once a gene of interest is identified, researchers can choose the appropriate tool and create a zebrafish to model an affected individual. The utility of the zebrafish model goes beyond modeling phenotypical characteristics. As a result of the zebrafish's highly conserved molecular pathways, downstream molecular analyses performed by isolating macromolecules from mutant embryos — including typical techniques such as quantitative real-time PCR (qRT-PCR), RNA-Seq, and Western blotting — can also be utilized to continue to investigate the underlying pathways of CCLA.

A proof-of-principle example has already been demonstrated, wherein a splice site *EPHB4* pathogenic variant was identified in an individual with CCLA and later modeled in Tg(*fli1*:EGFP) zebrafish using MO to knock down *ephb4* gene expression (Table 3) (94). The Tg(*fli1*:EGFP) zebrafish line enables researchers to visualized blood and lymphatic vessel formation during development (117). The model displayed misbranching of the intersegmental vessels and cystic formation in the caudal plexus. Treatment with mTORC1, MEK1/MEK2, or PI3K/mTOR inhibitors led to a significant reduction in misbranching and cyst formation, confirming that both pathways are important for the development of this phenotype. However, as in other applications, MO may induce off-target p53 effects and is diluted over time, which reduces their efficacy, and thus is not conducive to long-term examination (114).

Pathogenic variants in *ARAF*, *RIT1*, and *KRAS* were identified in individuals with CCLA (Table 1) (82, 85). Using the lymphatic- and venous-specific promotor *mrc1a* with Tol2-mediated transgenesis, researchers discovered that expression of these pathogenic variants led to pericardial edema and dilation of the thoracic duct (Table 3). In the ARAF-mutant model, treatment with cobi-

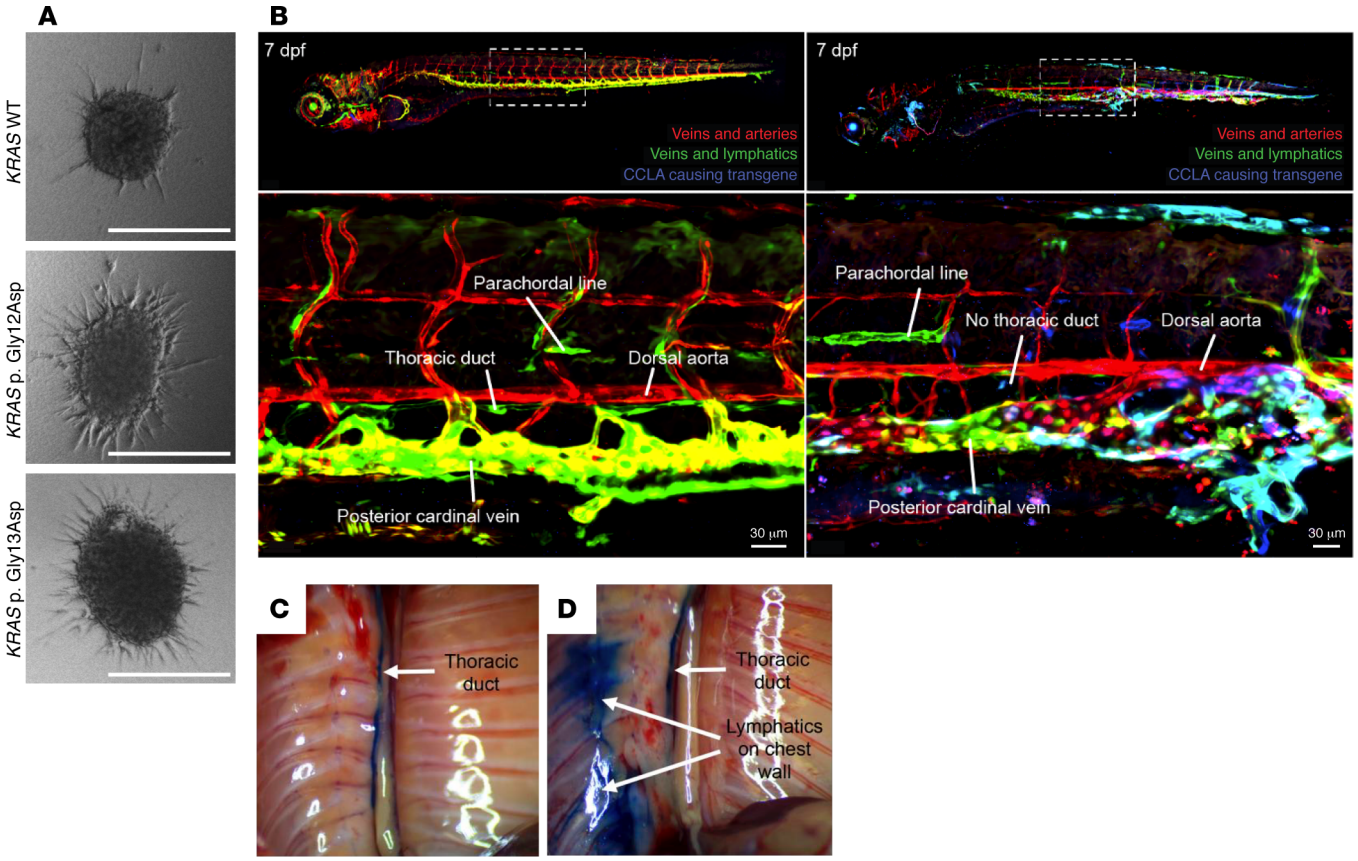

Figure 4. Examples of in vitro and in vivo assays to model CCLA. (**A**) In vitro organoid model. Lymphatic organoids were transduced with KRAS WT, KRAS p.Gly12Asp, or KRAS p.Gly13Asp and treated with DMSO (control); scale bars: 300 μm (images reproduced from ref. 85). (**B**) Zebrafish model of CCLA. Images of representative zebrafish 7 days post-fertilization (dpf) that were either uninjected or injected at the one-cell stage with a RASopathy-causing genetic variant under control of a lymphovenous (*mrc1a*) promoter. The top images show larvae that contain the Tg(*kdrl*:mCherry) transgene to label veins and arteries and Tg(*mrc1a*:EGFP) transgene to label veins and lymphatics. Additionally, the blue channel shows the mosaic expression of the *mrc1a*:RIT1:EBFP2 transgene, which causes profound lymphovenous malformations. The bottom images show the area within the dashed lines in the top images, labeled to highlight the morphological defects in the CCLA model fish. (**C** and **D**) Central lymphatics in iLEC^{Kras} mice were imaged on P20 with Evans blue dye. (**C**) The thoracic duct in iLEC^{Ctrl} mice (n = 4) filled with Evans blue dye (arrow). (**D**) The thoracic duct and lymphatics on the chest wall filled with Evans blue dye (arrows) in 4 of 6 iLEC^{Kras} mice. Images in **C** and **D** reproduced from ref. 24.

metinib, a MEK1/MEK2 inhibitor, resulted in significantly fewer larvae with severe dilation of the thoracic duct (82). Interestingly, in the KRAS-mutant models, there were genotype-specific differences. Treatment with sirolimus, an mTORC1 inhibitor, resulted in a significant reduction in the fraction of larvae with pericardial edema in the p.G13D but not the p.G12D model (85). In ongoing studies, approaches similar to those used for *KRAS* are being used to investigate pathogenic *RIT1* variants, with similar results (Figure 4B). These results suggest that some pathway inhibitors may be efficacious for RASopathies; however, there may be nuances in therapy based on genotype that still must be investigated. Overall, the benefits of the zebrafish model allow for quick, personalized-medicine approaches for investigating therapies.

Mice as a model for CCLA. Mice offer several benefits in biomedical research, including their phylogenetic and physiological similarity to humans, the ease of breeding and housing in a laboratory setting, and the commercial availability of inbred strains. One of the most powerful advances offered by this model is the rich toolbox of existing genetic tools including Cre/loxP recombination, tetracycline-inducible expression, CRISPR/Cas9 gene editing, Gateway transgenic recombination, and blastocyst chimeric injections (118). Genetic tools are used to induce expression of a certain gene or pathogenic variant in the specific cell populations or create a mutation in a mouse gene to produce a nonfunctional protein or completely prevent translation, called "knockin" or "knockout," lines respectively. Mice have proven to be an ideal system for studying vascular development on multiple levels, from LEC proliferation to postnatal vessel branching and vascular-disease progression through adulthood (3). Utilizing the previously mentioned techniques, researchers can genetically manipulate a certain target gene and then characterize vascular development to understand the pathway by which a certain genetic target affects lymphatic biology. Like DCMRL in humans, dynamic imaging can be performed to evaluate the structural and functional competence of lymphatic vessels by revealing the flow of fluorescent-labeled tracers or Evans blue dye through the thoracic duct and adjacent lymphatics in mice (Figure 4, C and D) (24).

Currently, there are few published mouse models for CCLA (Table 4). Using CRISPR/Cas9, researchers generated a loss-of-function mouse model to evaluate the involvement of *MDFIC*

Table 3. Zebrafish models of CCLA

Gene and identified variant	Protein function	Association with human disease	Zebrafish model used	Features of model	Therapeutics trialed	Reference
EPHB4; c.2334 + 1G>C	Receptor tyrosine kinase	AVMs, CCLA, LMs	MO	Caudal plexus defects and vessel misbranching	Rapamycin, BEZ235, U0126, and cobimetinib — all were successful at improving phenotype by 4 dpf	Li et al. 2018 (94)
ARAF; p.Ser214Pro	RAF kinase in MAPK signaling	Proto-oncogene, CCLA, RASopathies	Tol2 transgene	Thoracic duct dilation and ISV dilation	Cobimetinib improved thoracic duct dilation by 7 dpf	Li et al. 2019 (82)
KRAS; p.Gly12Asp, p.Gly13Asp, p.Ala146Thr	RAS-GTPase in MAPK signaling	CCLA, LMs, RASopathies	Tol2 transgene	Pericardial edema and intestinal edema	Cobimetinib, CI-1040, AZD8330, pimasertib, PD0325901, TAK-733, SL-327, BEZ-235, sirolimus, OSI-027, binimetinib, and pictilisib. There were mixed results across drugs between the Gly12Asp and Gly13Asp models.	Sheppard et al. 2023 (85); Li, Sheppard, et al. 2023 (48)

ISV, intersegmental vessels.

after biallelic variants were found in seven individuals affected by CCLA (95). Like the affected individuals, *Mdfic*$^{M131fs/M131fs}$ homozygous mice had congenital chylothorax (95). They also demonstrated dysmorphic thoracic duct and intercostal lymphatics with retrograde lymph flow, increased amounts of LYVE1-positive macrophages, and defective lymphatic valves, which resulted in total perinatal lethality by 30 days (95). RASA1 is a GTPase-activating regulator of blood and lymphatic vessel development and is an autosomal dominant cause of capillary malformation–arteriovenous malformation syndrome (CM-AVM) and CCLA in humans (119). Like humans, mice lacking *Rasa1* had extensive lymphatic vessel hyperplasia and leakage with chylothorax likely due to the loss of lymphatic endothelial cells in the valve leaflet (120–122). A RASA1 inducible-deletion model showed constitutive activation of Ras that led to LEC proliferation and lymphatic hyperplasia, which could be prevented through blocking the upstream growth factor receptor VEGFR-3 (121).

Other mouse models recapitulate other complex lymphatic anomalies and serve as a valuable tool for therapeutic screening in a bench-to-bedside model. A mouse model of GLA used the lymphatic vessel–specific Prox1-CreER^{T2} inducible mouse and LSL-Pik3ca^{H1047R} mice to drive expression of the p.His1047Arg somatic pathogenic *Pik3ca* variant in LECs expressing the fluorescent marker GFP (123). Rapamycin was shown to both prevent and improve progressive lymphatic vessel disease in mice and reduce pain and functionality in humans (123). *PIK3CA*$^{VEGFR3\text{-}CreER}$ mice expressed a constitutively active p110 protein chimera and developed phenotypes similar to those of humans, including vessel lymphatic malformations, chylothorax-associated lesions, gastrointestinal anomalies, and leaky vessels (124). Treatment with alpelisib (20 mg/kg), a PIK3CA inhibitor, starting on the last day of Cre induction rescued *PIK3CA*$^{VEGFR3\text{-}CreER}$ mice by restoring normal lymphatic vascular distribution and integrity by 30 days after induction and reducing the size of existing lymphatic malformations by an average of 90.6% (124). Gorham-Stout disease (GSD) has also been studied in the *iLEC*^{KRAS} mouse model using Prox1-CreER^{T2} to drive LEC-specific expression of KRAS (G12D), after an activating somatic variant in *KRAS* (G12V) was identified in one individual with GSD (24). The *iLEC*^{KRAS} model recapitulated phenotypes including the development of ectopic lymphatics in bone tissue; and changes to vessel structure, including lymphatic valve regression, which was shown to be prevented by treatment with trametinib from P0 to P12 (24). Interestingly, *iLEC*^{KRAS} mice showed abnormal posterior intercostal flow with IN injection, similar to the abnormal flow visualized by DCMRLs in humans with RASopathies (24, 61, 79–81).

Table 4. Mouse models of complex lymphatic anomalies

Gene and identified variant	Protein function	Association with human disease	Mouse model used	Features of model	Therapeutics trialed	Reference
PIK3CA; p.Glu542Lys, p.Gln546Lys, p.His1047Arg, p.His1047Leu	VEGFA signaling target in the regulation of endothelial cell migration and vascular development	PROS, CCLA, GLA, cancer	Selective Cre/Lox induction	Lymphatic hyperplasic, vessel dysfunction, pericardial effusions, lymphatic invasion of the bone	Sirolimus,[A] alpelisib	Rodriguez-Laguna et al. 2019 (123); Delestre et al. 2021 (124)
KRAS; p.Gly12Val	RAS-GTPase in MAPK signaling	GSD, CCLA, LMs, lymphedema, cancer	Selective Cre/Lox induction	Lymphatic valve regression, decreased lymphatic branching, lymphatic invasion of the bone, vessel dilation		Homayun-Sepehr et al. 2021 (24)
MDFIC; p.Met131Asnfs*3	MyoD family inhibitor domain–containing protein	CCLA, LMs	CRISPR/Cas9	Thoracic duct and lymphatic vessel dysfunction, increased number of LYVE1-positive macrophages, lymphatic valve dysfunction		Byrne et al. 2022 (95)

[A]The authors refer to sirolimus as rapamycin in ref. 123.

Table 5. Examples of therapy

Intervention	Mechanism of action	FDA approval	Reference
Sirolimus	mTOR inhibitor	Off-label use	Adams et al. 2016 (137); McCormick et al. 2016 (138); Agarwal et al. 2022 (139)
Alpelisib	Selective PI3Kα inhibitor	Yes	Li, Sheppard, et al. 2023 (48); Grenier et al. 2023 (97)
Trametinib	MEK1/2 inhibitor	Off-label use	Li et al. 2019 (82); Dori et al. 2020 (83); Gordon et al. 2022 (84); Nakano et al. 2022 (86); Lioncino et al. 2022 (140); Hribernik et al. 2023 (141); Sheppard et al. 2023 (85); Li, Sheppard, et al. 2023 (48)

Pathogenic variants in connexin genes cause lymphatic disease as a part of various syndromes in humans, and although CCLA has not been reported in these syndromes, evidence linking connexins to CCLA has been reported in mice. Variants in CX43, encoded by *GJA1*, and CX47, encoded by *GJC2*, cause lymphedema in humans, which can be a clinical manifestation of CCLA (125–127). In mice, loss of CX43 and CX37 led to lethal chylothorax, lymphedema, and bloody lymphatic vessels in the intestine and skin despite normal blood vasculature structure, whereas the lymphatic-specific ablation of CX43 resulted in a delay in lymphatic vessel formation — with fewer lymphatic valves that were immature and leaky due to incomplete leaflet elongation — but also lethal chylothorax (128, 129). Further research demonstrated significant valve defects; and evaluation of pressure back-leak in vessels through quantification of vessel dilation and use of the servo-null micropressure system demonstrated the valve leaflet regression and valve dysfunction observed in *Cx43*- and *Cx37*-mutant mice (130, 131).

Across the past two decades, researchers have used these genetic techniques to identify proteins important in lymphatic development that likely will be discovered as causes of CCLA. A novel adipocyte-specific VEGF-C overexpression model recapitulated the enlarged lymphatic vasculature and leakage phenotypes observed in human chylothorax patients when visualized with rhodamine-labeled *Ricinus communis* agglutinin I (RCA I) lectin tracer injection (132). $\alpha_9\beta_1$ Integrin is a receptor for extracellular adhesion proteins, such as osteopontin, tenascin-C, and vascular cell–specific immunoglobin adhesion molecules (133). Homozygous null mutants lacking the α_9 subunit developed edema and lymphatic vessel infiltration of the chest wall that ultimately led to death within 1–2 weeks due to accumulation of fluid in the lungs (133). A hypomorphic mutant lacking the NET DNA–binding domain, a serum response element repressor of vasculogenesis, showed vascular defects including lymphatic vessel dilation and chylothorax-induced respiratory failure (134). Loss of NET was associated with upregulation of EGR-1, a transcription factor known to be a downstream target of ERK and AKT signaling and activator of VEGF-A (134). Endothelial cell MAP4K4 has been shown to be essential to lymphatic vascular development by use of an endothelial cell–specific Cre-inducible loss-of-function mutant model (135). MAP4K4-deficient mice to develop lethal postnatal chylothorax in addition to lymphatic capillary dilation, reduced valve numbers in the collecting lymphatics, and impaired lymphatic flow (135).

Mouse models have proven to be a fruitful tool for expanding the currently limited body of research on lymphatic anomalies, including phenotypic modeling and development of targeted therapies. Additional techniques to isolate the endothelial cells from mouse collecting vessels in combination with in vitro systems can act in concert with mouse models to provide a deeper insight into the basic biology of lymphatic development and disease (136).

Targeted medical therapy for CCLA

The discovery of effective therapeutics in in vitro and in vivo models of CCLA have been translated to medical therapy for humans (Table 5). While early studies focused on using the mTOR inhibitor sirolimus (also known as rapamycin) agnostic of genetic cause, more recent studies have used other pathway inhibitors targeted to the molecular underpinnings of the disease.

Early trials focused on the use of sirolimus, an mTOR inhibitor, in vascular anomalies. The initial trial included only three participants with CCLA, who all had progressive disease while on treatment (137). However, an individual with CCLA had a reduction in chylous drainage after starting sirolimus, and another retrospective cohort study of infants with chylothorax due to GLA or CCLA found a reduction in mean duration with chest tube compared with prior studies (138, 139). As CCLA due to *PIK3CA* is rarer, there is less information about the use of alpelisib for CCLA. In one individual with features of CCLA and GLA due to a somatic pathogenic variant *PIK3CA*, there was reported improvement in lymphatic system function, as visualized by DCMRL, after initiation of alpelisib (48). There is crosstalk between the RAS and PI3K pathways, so in the future additional animal models or treatment trials may focus on combined therapy.

Given that the most common genetic causes of CCLA are activating variants in the RAS pathway, it is not surprising that initial studies targeting the RAS pathway demonstrated efficacy. The initial studies in zebrafish modeling *ARAF* variants paved the way for trialing therapy with the MEK inhibitor trametinib in a single case study (82). This individual affected with CCLA and lymphedema due to *ARAF* had improvement on pulmonary function tests, reduction in lymphatic fluid retention, decrease in supplemental oxygen requirements, and altered flow as visualized by DCMRL (82). Subsequently, trametinib was used to treat an individual with Noonan syndrome caused by a *SOS1* variant (*SOS1*–Noonan syndrome) and CCLA manifesting as protein-losing enteropathy (83). Trametinib treatment resulted in normalization of albumin level within 3 months of therapy (83). In an infant with *SOS1*–Noonan syndrome and pulmonary lymphangiectasia and pleural effusions requiring invasive ventilation, trametinib treatment resulted in resolution of the effusions within 1 week and transition to room air after 3 weeks (140). In an adult with *RIT1*–Noonan syndrome and lymphatic failure, trametinib therapy resulted in increased albumin level, resolution of ascites in 3 months, and reduction of pericardial effusion within 18 months (84). Similarly, in a child with *RIT1*–Noonan syndrome who had chylous pleural effusions

drained at the initiation of a 3-month course of trametinib, the effusions did not recur (141). In another case series, three infants with Noonan syndrome (*SOS1*, *RIT1*, *PTPN11*) all had a reduction in chylous effusions, chylous ascites, and improvement in respiratory status with trametinib therapy (86). Although many of these single cases show success, there have been no clinical trials yet to truly assess the safety and efficacy of trametinib or other MEK inhibitors in the treatment of CCLA.

Therapies targeted to an individual's dysregulated molecular pathway in combination with conservative management have resulted in improved outcomes for individuals with CCLA. These medicines may obviate the need for more-traditional management or may be combined with conservative management for the best outcome.

Conclusion

CCLA is a complex lymphatic anomaly that has historically been difficult to diagnose and treat. Advances in imaging and genomics have improved diagnosis and refined understanding of both genotype and phenotype. Further clinical development of liquid biopsy will allow for noninvasive genetic diagnosis. In vitro and in vivo models have validated various candidate genes that cause CCLA and defined the underlying pathogenesis. These affected individual–based models facilitated development of personalized therapeutics targeted to genetic cause, resulting in improved outcomes. Continued collaboration between basic scientists and clinicians will continue to drive forward the science to understand the molecular underpinnings of CCLA, visualize the lymphatic system, and identify pharmaceutical treatments to improve outcomes in individuals with CCLA.

Acknowledgments

The authors thank Ethan Tyler of NIH Medical Arts for his initial draft of Figure 1C. LDGT, BAS, GLK, KMW, SMP, and SES are supported by the *Eunice Kennedy Shriver* National Institute of Child Health and Human Development under award HD009003-01. The content is solely the responsibility of the authors and does not necessarily represent the official views of the NIH.

Address correspondence to: Sarah E. Sheppard, 10 Center Drive, MSC 1103, Bethesda, Maryland 20892-1103, USA. Phone: 240.578.5047; Email: sarah.sheppard@nih.gov.

1. Oliver G, et al. The lymphatic vasculature in the 21st century: novel functional roles in homeostasis and disease. *Cell*. 2020;182(2):270–296.
2. Cueni LN, Detmar M. The lymphatic system in health and disease. *Lymphat Res Biol*. 2008;6(3-4):109–122.
3. Mäkinen T, et al. Lymphatic malformations: genetics, mechanisms and therapeutic strategies. *Circ Res*. 2021;129(1):136–154.
4. Louveau A, et al. Structural and functional features of central nervous system lymphatic vessels. *Nature*. 2015;523(7560):337–341.
5. Aspelund A, et al. A dural lymphatic vascular system that drains brain interstitial fluid and macromolecules. *J Exp Med*. 2015;212(7):991–999.
6. Hogan BM, et al. Ccbe1 is required for embryonic lymphangiogenesis and venous sprouting. *Nat Genet*. 2009;41(4):396–398.
7. Jeltsch M, et al. CCBE1 enhances lymphangiogenesis via A disintegrin and metalloprotease with thrombospondin motifs-3-mediated vascular endothelial growth factor-C activation. *Circulation*. 2014;129(19):1962–1971.
8. Guen LL, et al. Ccbe1 regulates Vegfc-mediated induction of Vegfr3 signaling during embryonic lymphangiogenesis. *Development*. 2014;141(6):1239–1249.
9. Bui HM, et al. Proteolytic activation defines distinct lymphangiogenic mechanisms for VEGFC and VEGFD. *J Clin Invest*. 2016;126(6):2167–2180.
10. Jha SK, et al. Efficient activation of the lymphangiogenic growth factor VEGF-C requires the C-terminal domain of VEGF-C and the N-terminal domain of CCBE1. *Sci Rep*. 2017;7(1):4916.
11. Jerafi-Vider A, et al. VEGFC/FLT4-induced cell-cycle arrest mediates sprouting and differentiation of venous and lymphatic endothelial cells. *Cell Rep*. 2021;35(11):109255.
12. Shin M, et al. Vegfc acts through ERK to induce sprouting and differentiation of trunk lymphatic progenitors. *Development*. 2016;143(20):3785–3795.
13. Sabine A, et al. Mechanotransduction, PROX1, and FOXC2 cooperate to control connexin37 and calcineurin during lymphatic-valve formation. *Dev Cell*. 2012;22(2):430–445.
14. Kazenwadel J, et al. GATA2 is required for lymphatic vessel valve development and maintenance. *J Clin Invest*. 2015;125(8):2979–2994.
15. Kazenwadel J, et al. Loss-of-function germline GATA2 mutations in patients with MDS/AML or MonoMAC syndrome and primary lymphedema reveal a key role for GATA2 in the lymphatic vasculature. *Blood*. 2012;119(5):1283–1291.
16. Altiok E, et al. Integrin alpha-9 mediates lymphatic valve formation in corneal lymphangiogenesis. *Invest Ophthalmol Vis Sci*. 2015;56(11):6313–6319.
17. Bazigou E, et al. Integrin-alpha9 is required for fibronectin matrix assembly during lymphatic valve morphogenesis. *Dev Cell*. 2009;17(2):175–186.
18. Shin M, et al. Valves are a conserved feature of the zebrafish lymphatic system. *Dev Cell*. 2019;51(3):374–386.
19. Choi D, et al. Piezo1-regulated mechanotransduction controls flow-activated lymphatic expansion. *Circ Res*. 2022;131(2):e2–e21.
20. Nonomura K, et al. Mechanically activated ion channel PIEZO1 is required for lymphatic valve formation. *Proc Natl Acad Sci U S A*. 2018;115(50):12817–12822.
21. Zhang G, et al. EphB4 forward signalling regulates lymphatic valve development. *Nat Commun*. 2015;6(1):6625.
22. Yang Y, et al. VE-cadherin is required for lymphatic valve formation and maintenance. *Cell Rep*. 2019;28(9):2397–2412.
23. Scallan JP, et al. Foxo1 deletion promotes the growth of new lymphatic valves. *J Clin Invest*. 2021;131(14):e142341.
24. Homayun-Sepehr NH, et al. KRAS-driven model of Gorham-Stout disease effectively treated with trametinib. *JCI Insight*. 2021;6(15):e149831.
25. Randolph GJ, et al. The lymphatic system: integral roles in immunity. *Annu Rev Immunol*. 2015;35(1):31–52.
26. Yaniv K, et al. Live imaging of lymphatic development in the zebrafish. *Nat Med*. 2006;12(6):711–716.
27. Okuda KS, et al. lyve1 expression reveals novel lymphatic vessels and new mechanisms for lymphatic vessel development in zebrafish. *Development*. 2012;139(13):2381–2391.
28. Küchler AM, et al. Development of the zebrafish lymphatic system requires VEGFC signaling. *Curr Biol*. 2006;16(12):1244–1248.
29. Karkkainen MJ, et al. Vascular endothelial growth factor C is required for sprouting of the first lymphatic vessels from embryonic veins. *Nat Immunol*. 2004;5(1):74–80.
30. Wigle JT, Oliver G. Prox1 function is required for the development of the murine lymphatic system. *Cell*. 1999;98(6):769–778.
31. Yang Y, et al. Lymphatic endothelial progenitors bud from the cardinal vein and intersomitic vessels in mammalian embryos. *Blood*. 2012;120(11):2340–2348.
32. François M, et al. Segmental territories along the cardinal veins generate lymph sacs via a ballooning mechanism during embryonic lymphangiogenesis in mice. *Dev Biol*. 2012;364(2):89–98.
33. Hägerling R, et al. A novel multistep mechanism for initial lymphangiogenesis in mouse embryos based on ultramicroscopy. *EMBO J*. 2013;32(5):629–644.
34. Ny A, et al. A genetic Xenopus laevis tadpole model to study lymphangiogenesis. *Nat Med*. 2005;11(9):998–1004.
35. Buttler K, et al. Mesenchymal cells with leukocyte and lymphendothelial characteristics in murine embryos. *Dev Dyn*. 2006;235(6):1554–1562.
36. Wigle JT, et al. An essential role for Prox1 in the induction of the lymphatic endothelial cell phe-

notype. *EMBO J*. 2002;21(7):1505–1513.
37. Wilting J, et al. Dual origin of avian lymphatics. *Dev Biol*. 2006;292(1):165–173.
38. Srinivasan RS, et al. Lineage tracing demonstrates the venous origin of the mammalian lymphatic vasculature. *Genes Dev*. 2007;21(19):2422–2432.
39. Stanczuk L, et al. cKit lineage hemogenic endothelium-derived cells contribute to mesenteric lymphatic vessels. *Cell Rep*. 2015;10(10):1708–1721.
40. Klotz L, et al. Cardiac lymphatics are heterogeneous in origin and respond to injury. *Nature*. 2015;522(7554):62–67.
41. Martinez-Corral I, et al. Nonvenous origin of dermal lymphatic vasculature. *Circ Res*. 2015;116(10):1649–1654.
42. Pichol-Thievend C, et al. A blood capillary plexus-derived population of progenitor cells contributes to genesis of the dermal lymphatic vasculature during embryonic development. *Development*. 2018;145(10):dev160184.
43. Pamarthi V, et al. MRI of the central lymphatic system: indications, imaging technique, and pre-procedural planning. *Top Magn Reson Imaging*. 2017;26(4):175–180.
44. Ricci KW, Iacobas I. How we approach the diagnosis and management of complex lymphatic anomalies. *Pediatr Blood Cancer*. 2022;69(suppl 3):e28985.
45. Adams DM, Ricci KW. Vascular anomalies: diagnosis of complicated anomalies and new medical treatment options. *Hematol Oncol Clin North Am*. 2019;33(3):455–470.
46. Trenor CC, Chaudry G. Complex lymphatic anomalies. *Semin Pediatr Surg*. 2014;23(4):186–190.
47. Chaudry G. Complex lymphatic anomalies and therapeutic options. *Tech Vasc Interv Radiol*. 2019;22(4):100632.
48. Li D, et al. Genomic profiling informs diagnoses and treatment in vascular anomalies. *Nat Med*. 2023;29(6):1530–1539.
49. Ozeki M, et al. Clinical features and prognosis of generalized lymphatic anomaly, kaposiform lymphangiomatosis, and gorham-stout disease. *Pediatr Blood Cancer*. 2016;63(5):832–838.
50. Perez-Atayde AR, et al. Kaposiform lymphangiomatosis: pathologic aspects in 43 patients. *Am J Surg Pathol*. 2022;46(7):963–976.
51. McDaniel CG, et al. Kaposiform lymphangiomatosis: diagnosis, pathogenesis, and treatment. *Pediatr Blood Cancer*. 2023;70(4):e30219.
52. Goyal P, et al. Imaging features of kaposiform lymphangiomatosis. *Pediatr Radiol*. 2016;46(9):1282–1290.
53. Croteau SE, et al. Kaposiform lymphangiomatosis: a distinct aggressive lymphatic anomaly. *J Pediatr*. 2014;164(2):383–388.
54. Dellinger MT, et al. Viewpoints on vessels and vanishing bones in Gorham-Stout disease. *Bone*. 2014;63:47–52.
55. Gorham LW, et al. Disappearing bones: a rare form of massive osteolysis; report of two cases, one with autopsy findings. *Am J Med*. 1954;17(5):674–682.
56. Gorham LW, Stout AP. Hemangiomatosis and its relation to massive osteolysis. *Trans Assoc Am Physicians*. 1954;67:302–307.
57. Kato H, et al. Chest imaging in generalized lymphatic anomaly and kaposiform lymphangiomatosis. *Pediatr Int*. 2018;60(7):667–668.
58. Nriagu BN, et al. Multicompartment dynamic contrast magnetic resonance lymphangiography in diagnosis of complicated lymphatic anomaly. *Lymphat Res Biol*. 2023;21(2):135–140.
59. Lee Y, et al. The spectrum of imaging manifestations of Gorham-Stout disease: a novel dynamic contrast-enhanced MR lymphangiography. *Orphanet J Rare Dis*. 2023;18(1):96.
60. Ahn Y, et al. Dynamic contrast-enhanced magnetic resonance lymphangiography and lymphatic interventions for pediatric patients with various lymphatic diseases. *Lymphat Res Biol*. 2023;21(2):141–151.
61. Liu M, et al. Genetics etiologies and genotype phenotype correlations in a cohort of individuals with central conducting lymphatic anomaly. *Eur J Hum Genet*. 2022;30(9):1094.
62. Dori Y, Smith CL. Lymphatic disorders in patients with single ventricle heart disease. *Front Pediatr*. 2022;10:828107.
63. Ramirez-Suarez KI, et al. Lymphatic anomalies in congenital heart disease. *Pediatr Radiol*. 2022;52(10):1862–1876.
64. Biko DM, et al. Pediatric pulmonary lymphatic flow disorders: diagnosis and management. *Paediatr Respir Rev*. 2019;36:2–7.
65. Mackie AS, et al. Plastic bronchitis and protein-losing enteropathy in the fontan patient: evolving understanding and emerging therapies. *Can J Cardiol*. 2022;38(7):988–1001.
66. De-xin Y, et al. Morphological features and clinical feasibility of thoracic duct: detection with nonenhanced magnetic resonance imaging at 3.0 T. *J Magn Reson Imaging*. 2010;32(1):94–100.
67. Takahashi H, et al. Clinical feasibility of noncontrast-enhanced magnetic resonance lymphography of the thoracic duct. *Chest*. 2003;124(6):2136–2142.
68. Dori Y. Novel lymphatic imaging techniques. *Tech Vasc Interv Radiol*. 2016;19(4):255–261.
69. Ramirez-Suarez KI, et al. Dynamic contrast-enhanced magnetic resonance lymphangiography. *Pediatr Radiol*. 2022;52(2):285–294.
70. Ramirez-Suarez KI, et al. State-of-the-art imaging for lymphatic evaluation in children. *Pediatr Radiol*. 2023;53(7):1380–1390.
71. Dori Y, et al. Dynamic contrast-enhanced MR lymphangiography: feasibility study in swine. *Radiology*. 2014;273(2):410–416.
72. Krishnamurthy R, et al. Imaging the central conducting lymphatics: initial experience with dynamic MR lymphangiography. *Radiology*. 2015;274(3):871–878.
73. Itkin M, Nadolski GJ. Modern techniques of lymphangiography and interventions: current status and future development. *Cardiovasc Intervent Radiol*. 2018;41(3):366–376.
74. Turkbey B, et al. Magnetic resonance lymphography of the thoracic duct after interstitial injection of gadofosveset trisodium: a pilot dosing study in a porcine model. *Lymphat Res Biol*. 2014;12(1):32–36.
75. Rajebi MR, et al. Intranodal lymphangiography: feasibility and preliminary experience in children. *J Vasc Interv Radiol*. 2011;22(9):1300–1305.
76. Biko DM, et al. Intrahepatic dynamic contrast MR lymphangiography: initial experience with a new technique for the assessment of liver lymphatics. *Eur Radiol*. 2019;29(10):5190–5196.
77. Dori Y, et al. Intramesenteric dynamic contrast pediatric MR lymphangiography: initial experience and comparison with intranodal and intrahepatic MR lymphangiography. *Eur Radiol*. 2020;30(10):5777–5784.
78. Simon M, et al. Alternative evaluation of the right axillary lymphatic pathway by using dynamic contrast-enhanced MR lymphangiography. *Radiol Cardiothorac Imaging*. 2022;4(5):e220035.
79. Biko DM, et al. Imaging of central lymphatic abnormalities in Noonan syndrome. *Pediatr Radiol*. 2019;49(5):586–592.
80. Kleimeier LER, et al. Lymphatic phenotype of noonan syndrome: innovative diagnosis and possible implications for therapy. *J Clin Med*. 2022;11(11):3128.
81. Pieper CC, et al. MR lymphangiography of lymphatic abnormalities in children and adults with Noonan syndrome. *Sci Rep*. 2022;12(1):11164.
82. Li D, et al. ARAF recurrent mutation causes central conducting lymphatic anomaly treatable with a MEK inhibitor. *Nat Med*. 2019;25(7):1116–1122.
83. Dori Y, et al. Severe lymphatic disorder resolved with mek inhibition in a patient with noonan syndrome and SOS1 mutation. *Pediatrics*. 2020;146(6):e20200167.
84. Gordon K, et al. Case report: progressive central conducting lymphatic abnormalities in the RASopathies. Two case reports, including successful treatment by MEK inhibition. *Front Genet*. 2022;13:1001105.
85. Sheppard SE, et al. Lymphatic disorders caused by mosaic, activating KRAS variants respond to MEK inhibition. *JCI Insight*. 2023;8(9):e155888.
86. Nakano TA, et al. Trametinib for refractory chylous effusions and systemic complications in children with noonan syndrome. *J Pediatr*. 2022;248:81–88.
87. Pham KT, et al. Multimodality lymphatic imaging of postoperative chylothorax in an infant with Noonan syndrome: a case report. *Eur J Med Res*. 2020;25(1):55.
88. Mologousis MA, et al. Spectrum of lymphatic anomalies in patients with RASA1-related CM-AVM. *Pediatr Dermatol*. 2023;40(6):1028–1034.
89. Lapinski PE, et al. Somatic second hit mutation of RASA1 in vascular endothelial cells in capillary malformation-arteriovenous malformation. *Eur J Med Genet*. 2018;61(1):11–16.
90. Macmurdo CF, et al. RASA1 somatic mutation and variable expressivity in capillary malformation/arteriovenous malformation (CM/AVM) syndrome. *Am J Med Genet A*. 2016;170(6):1450–1454.
91. Revencu N, et al. Parkes Weber syndrome, vein of Galen aneurysmal malformation, and other fast-flow vascular anomalies are caused by RASA1 mutations. *Hum Mutat*. 2008;29(7):959–965.
92. Revencu N, et al. RASA1 mutations and associated phenotypes in 68 families with capillary malformation-arteriovenous malformation. *Hum Mutat*. 2013;34(12):1632–1641.
93. Wijn RS de, et al. Phenotypic variability in a family with capillary malformations caused by a mutation in the RASA1 gene. *Eur J Med Genet*. 2012;55(3):191–195.
94. Li D, et al. Pathogenic variant in EPHB4 results in central conducting lymphatic anomaly. *Hum Mol*

Genet. 2018;27(18):3233–3245.
95. Byrne AB, et al. Pathogenic variants in *MDFIC* cause recessive central conducting lymphatic anomaly with lymphedema. *Sci Transl Med*. 2022;14(634):eabm4869.
96. Li D, et al. Expanded phenotypic spectrum of JAG1-associated diseases: central conducting lymphatic anomaly with a pathogenic variant in JAG1. *Clin Genet*. 2021;99(5):742–743.
97. Grenier JM, et al. Pathogenic variants in PIK-3CA are associated with clinical phenotypes of kaposiform lymphangiomatosis, generalized lymphatic anomaly, and central conducting lymphatic anomaly [published online May 17, 2023]. *Pediatr Blood Cancer*. https://doi.org/10.1002/pbc.30419.
98. Traub ES, et al. Chromosome 4q28.3q32.3 duplication in a patient with lymphatic malformations, craniosynostosis, and dysmorphic features. *Clin Dysmorphol*. 2021;30(2):89–92.
99. McNulty SN, et al. Diagnostic utility of next-generation sequencing for disorders of somatic mosaicism: a five-year cumulative cohort. *Am J Hum Genet*. 2019;105(4):734–746.
100. Michelini S, et al. Genetic tests in lymphatic vascular malformations and lymphedema. *J Med Genet*. 2018;55(4):222–232.
101. Oliver G, Kahn ML, eds. *Lymphangiogenesis: Methods and Protocols*. Springer; 2018.
102. Sato M, et al. Microcirculation-on-a-chip: a microfluidic platform for assaying blood- and lymphatic-vessel permeability. *PLoS One*. 2015;10(9):e0137301.
103. Cao X, et al. A tumor-on-a-chip system with bioprinted blood and lymphatic vessel pair. *Adv Funct Mater*. 2019;29(31):1807173.
104. Selahi A, et al. Lymphangion-chip: a microphysiological system which supports co-culture and bidirectional signaling of lymphatic endothelial and muscle cells. *Lab Chip*. 2021;22(1):121–135.
105. Wu JK, et al. Aberrant lymphatic endothelial progenitors in lymphatic malformation development. *PLoS One*. 2015;10(2):e0117352.
106. Blesinger H, et al. PIK3CA mutations are specifically localized to lymphatic endothelial cells of lymphatic malformations. *PLoS One*. 2018;13(7):e0200343.
107. Santoro MM, et al. Advantages and challenges of cardiovascular and lymphatic studies in zebrafish research. *Front Cell Dev Biol*. 2019;7:89.
108. Jung HM, et al. Chapter 4 imaging blood vessels and lymphatic vessels in the zebrafish. *Methods Cell Biol*. 2016;133:69.
109. Padberg Y, et al. Chapter 9 The lymphatic vasculature revisited—new developments in the zebrafish. *Methods Cell Biol*. 2017;138:221.
110. Jung HM, et al. Development of the larval lymphatic system in zebrafish. *Development*. 2017;144(11):2070–2081.
111. Isogai S, et al. Zebrafish as a new animal model to study lymphangiogenesis. *Anat Sci Int*. 2009;84(3):102–111.
112. Impel A van, et al. Divergence of zebrafish and mouse lymphatic cell fate specification pathways. *Development*. 2014;141(6):1228–1238.
113. Lawson ND, Wolfe SA. Forward and reverse genetic approaches for the analysis of vertebrate development in the zebrafish. *Dev Cell*. 2011;21(1):48–64.
114. Kok FO, et al. Reverse genetic screening reveals poor correlation between morpholino-induced and mutant phenotypes in zebrafish. *Dev Cell*. 2015;32(1):97–108.
115. Kawakami K, et al. A transposon-mediated gene trap approach identifies developmentally regulated genes in zebrafish. *Dev Cell*. 2004;7(1):133–144.
116. Kawakami K. Transgenesis and gene trap methods in zebrafish by using the Tol2 transposable element. *Methods Cell Biol*. 2004;77:201–222.
117. Lawson ND, Weinstein BM. In vivo imaging of embryonic vascular development using transgenic zebrafish. *Dev Biol*. 2002;248(2):307–318.
118. Wetzel-Strong SE, et al. The pathobiology of vascular malformations: insights from human and model organism genetics. *J Pathol*. 2017;241(2):281–293.
119. Eerola I, et al. Capillary malformation-arteriovenous malformation, a new clinical and genetic disorder caused by RASA1 mutations. *Am J Hum Genet*. 2003;73(6):1240–1249.
120. Burrows PE, et al. Lymphatic abnormalities are associated with RASA1 gene mutations in mouse and man. *Proc Natl Acad Sci U S A*. 2013;110(21):8621–8626.
121. Lapinski PE, et al. RASA1 maintains the lymphatic vasculature in a quiescent functional state in mice. *J Clin Invest*. 2012;122(2):733–747.
122. Lapinski PE, et al. RASA1 regulates the function of lymphatic vessel valves in mice. *J Clin Invest*. 2017;127(7):2569–2585.
123. Rodriguez-Laguna L, et al. Somatic activating mutations in *PIK3CA* cause generalized lymphatic anomaly. *J Exp Med*. 2019;216(2):407–418.
124. Delestre F, et al. Alpelisib administration reduced lymphatic malformations in a mouse model and in patients. *Sci Transl Med*. 2021;13(614):eabg0809.
125. Ferrell RE, et al. GJC2 missense mutations cause human lymphedema. *Am J Hum Genet*. 2010;86(6):943–948.
126. Brice G, et al. A novel mutation in GJA1 causing oculodentodigital syndrome and primary lymphoedema in a three generation family. *Clin Genet*. 2013;84(4):378–381.
127. Gumus E. A rare symptom of a very rare disease: a case report of a oculodentodigital dysplasia with lymphedema. *Clin Dysmorphol*. 2018;27(3):91–93.
128. Kanady JD, et al. Connexin37 and Connexin43 deficiencies in mice disrupt lymphatic valve development and result in lymphatic disorders including lymphedema and chylothorax. *Dev Biol*. 2011;354(2):253–266.
129. Munger SJ, et al. Defective lymphatic valve development and chylothorax in mice with a lymphatic-specific deletion of Connexin43. *Dev Biol*. 2017;421(2):204–218.
130. Castorena-Gonzalez JA, et al. Mechanisms of connexin-related lymphedema. *Circ Res*. 2018;123(8):964–985.
131. Castorena-Gonzalez JA, et al. Simplified method to quantify valve back-leak uncovers severe mesenteric lymphatic valve dysfunction in mice deficient in connexins 43 and 37. *J Physiol*. 2020;598(12):2297–2310.
132. Nitschké M, et al. Retrograde lymph flow leads to chylothorax in transgenic mice with lymphatic malformations. *Am J Pathol*. 2017;187(9):1984–1997.
133. Huang XZ, et al. Fatal bilateral chylothorax in mice lacking the integrin alpha9beta1. *Mol Cell Biol*. 2000;20(14):5208–5215.
134. Ayadi A, et al. Net-targeted mutant mice develop a vascular phenotype and up-regulate egr-1. *EMBO J*. 2001;20(18):5139–5152.
135. Flach RJR, et al. Endothelial mitogen-activated protein kinase kinase kinase kinase 4 is critical for lymphatic vascular development and function. *Mol Cell Biol*. 2016;36(12):1740–1749.
136. Jablon KL, et al. Isolation and short-term culturing of primary lymphatic endothelial cells from collecting lymphatics: a techniques study. *Microcirculation*. 2023;30(2-3):e12778.
137. Adams DM, et al. Efficacy and safety of sirolimus in the treatment of complicated vascular anomalies. *Pediatrics*. 2016;137(2):e20153257.
138. McCormick A, et al. A case of a central conducting lymphatic anomaly responsive to sirolimus. *Pediatrics*. 2016;137(1):e20152694.
139. Agarwal S, et al. Sirolimus efficacy in the treatment of critically ill infants with congenital primary chylous effusions. *Pediatr Blood Cancer*. 2022;69(2):e29510.
140. Lioncino M, et al. Severe lymphatic disorder and multifocal atrial tachycardia treated with trametinib in a patient with noonan syndrome and SOS1 mutation. *Genes (Basel)*. 2022;13(9):1503.
141. Hribernik I, et al. Successful treatment of refractory chylothorax with MEK inhibitor trametinib in a child with Noonan syndrome: case report. *Eur Heart J Case Rep*. 2023;7(4):ytad190.
142. Liu NF, Gao MZ. Lymphatic system malformations in Noonan syndrome: two case reports and imaging analysis. *Lymphology*. 2020;53(2):76–80.
143. Othman S, et al. Respiratory failure in noonan syndrome treated by microsurgical thoracic duct-venous anastomosis. *Ann Thorac Surg*. 2022;113(3):e219–e221.
144. Keberle M, et al. Computed tomography after lymphangiography in the diagnosis of intestinal lymphangiectasia with protein-losing enteropathy in Noonan's syndrome. *Eur Radiol*. 2000;10(10):1591–1593.
145. Matsumoto T, et al. Transnodal lymphangiography and post-CT for protein-losing enteropathy in Noonan syndrome. *Minim Invasive Ther Allied Technol*. 2015;24(4):246–249.